



Contents lists available at ScienceDirect

# European Journal of Obstetrics & Gynecology and Reproductive Biology

journal homepage: [www.elsevier.com/locate/ejogrb](http://www.elsevier.com/locate/ejogrb)

Full length article

## Safety and long-term efficacy of fractional CO<sub>2</sub> laser treatment in women suffering from genitourinary syndrome of menopause<sup>☆</sup>



Fariba Behnia-Willison<sup>a</sup>, Sara Sarraf<sup>b</sup>, Joseph Miller<sup>c,\*</sup>, Behrang Mohamadi<sup>d</sup>,  
Alison S. Care<sup>c,i</sup>, Alan Lam<sup>e</sup>, Nadia Willison<sup>f</sup>, Leila Behnia<sup>g</sup>, Stefano Salvatore<sup>h</sup>

<sup>a</sup> FBW Gynaecology Plus, Flinders Medical Centre, Flinders University, Australia<sup>b</sup> Virginia Women's Center, St. Francis Medical Center, Memorial Regional Medical Center, St. Mary's Hospital, United States<sup>c</sup> The University of Adelaide, Australia<sup>d</sup> FBW Gynaecology Plus, Australia<sup>e</sup> Centre for Advanced Reproductive Endosurgery, Australia<sup>f</sup> Flinders University, Australia<sup>g</sup> University of Tehran, Iran<sup>h</sup> San Raffaele University, San Raffaele Hospital, Italy<sup>i</sup> Robinson Research Institute, The University of Adelaide, Australia

## ARTICLE INFO

## Article history:

Received 1 November 2016

Received in revised form 8 March 2017

Accepted 25 March 2017

Available online xxx

## Keywords:

Genitourinary syndrome of menopause  
MenopauseFractional CO<sub>2</sub> laser

Sexual function

Bladder control

## ABSTRACT

**Objectives:** To evaluate the safety and long-term efficacy of fractional CO<sub>2</sub> laser treatment in reducing the severity of symptoms of genitourinary syndrome of menopause (GSM) in menopausal women.

**Study design:** 102 women presenting with symptomatic GSM were treated with the fractional CO<sub>2</sub> laser (MonaLisa Touch, DEKA) system across a series of treatments delivered at intervals of six or more weeks. The Australian Pelvic Floor Questionnaire was used to gather data on sexual function and side-effects at three time-points across the study period (prospective panel design study). Wilcoxon signed-rank tests were used to detect statistically and clinically significant changes in sexual function and side-effects occurring from pre- to post-treatment. The primary outcome of this study was an improvement of the symptoms of GSM. The secondary outcome included bladder function and prolapse symptoms.

**Results:** A total of 102 women suffering from moderate to severe GSM were recruited. Eighty-four percent experienced significant improvement in their symptoms after CO<sub>2</sub> laser treatment. Scores on measures of sexual function, dyspareunia, and bothersomeness of sexual issues were improved from pre-treatment to long-term (12–24 month) follow-up. Furthermore, there were improvements on measures of bladder function ( $P = 0.001$ ), prolapse ( $P = 0.001$ ), vaginal sensation ( $P = 0.001$ ), vaginal lubrication ( $P < 0.001$ ) and urge incontinence ( $P = 0.003$ ) from the pre-treatment assessment to the second assessment (i.e. after the third treatment).

**Conclusions:** In this study, fractional microablative CO<sub>2</sub> laser treatment was associated with an improvement in symptoms of GSM and sexual function.

© 2017 Published by Elsevier Ireland Ltd.

## Introduction

Life expectancy for women has increased significantly during the past century and many women will now spend more than one third of their lives in menopause [1,2]. Many of these postmenopausal women, who expect to maintain good health and a high quality of life into their postmenopausal years, consider sexual

health and relationship satisfaction to be of paramount importance.

The sexual health of postmenopausal women can be undermined by the progressive ageing of the body, as well as by genitourinary syndrome of menopause (GSM) [3]. GSM, previously known as atrophic vaginitis, is a multifaceted oestrogen-dependent condition which often occurs as a manifestation of meno-

<sup>☆</sup> Acknowledgement: This research would not have been possible without the support of the wonderful staff at FBW Gynaecology Plus.

\* Corresponding author.

E-mail address: [millerjoe1988@gmail.com](mailto:millerjoe1988@gmail.com) (J. Miller).

pause [4]. The fall in oestrogen resulting from menopause causes the vaginal epithelium to become thin and pale [1], lose vascularity, collagen fibres, leading to decreased engorgement, lubrication, and reduced elasticity. Vaginal smears of patients suffering from GSM demonstrate a unique morphology whereby superficial cells are scant and there is an increase in intermediate and parabasal cells in hypoestrogenemic conditions, which, along with decreased glycogen-rich cells, promotes increased vaginal pH [5]. These conditions increase the risk of developing symptoms such as dryness, burning, itching, irritation, abnormal discharge, recurrent thrush and dyspareunia, which are likely to cause an altered response to sexual stimuli [4]. This discomfort associated with intercourse often leads to a vicious cycle of decreased desire, arousal, orgasm and frequency of coitus, resulting in loss of self-confidence and depression throughout the pre- and postmenopausal stages [6].

It is estimated that about 8–22% of premenopausal women and 40–57% of postmenopausal women experience symptoms resulting from GSM [7]. However, only 1 in 5 women experiencing these symptoms will consult a physician on issues related to GSM [1]. Current therapies for GSM include hormonal therapy with oestrogen alone (ET) and oestrogen-progestin therapy (EPT). Whilst these therapies may be effective in increasing vaginal

lubrication and reducing dyspareunia, they have not been shown to consistently increase sexual desire or activity [8].

Due to embryological origin, the lower one third of the vagina (like the urethra and bladder) has fewer oestrogen receptors than the upper two thirds, which may impact the effect of hormonal therapy on the lower third [7,9]. For this reason, hormonal therapy is not particularly effective as a treatment for superficial dyspareunia. In addition, a subgroup of women demonstrates contraindications to hormonal therapy or experiences relapse shortly after treatment [8]. The rate of medical adherence to this line of therapy is quite variable (52–74%) mainly due to safety concerns, inconvenience, and inadequate symptom relief from available treatments [10,11]. There is a lack of long-term safety data for vaginal hormonal therapy and the important question of whether it is safe to use local oestrogen treatment in cancer survivors remains unanswered [2]. Regardless, patients diagnosed with breast cancer are often reluctant to use oestrogen treatment. Therefore, the need to consider non-pharmacological approaches is essential.

Fractional micro-ablative CO<sub>2</sub> laser represents one potential non-pharmacological approach to GSM. Broadly speaking, laser treatments employ heat to improve the collagen structure of tissue [12]. Fractional micro-ablative CO<sub>2</sub> laser achieves its effects by

**Table 1**  
Summary of results from studies investigating fractional CO<sub>2</sub> laser as a treatment for GSM.

First author (year of publication)	Study population (n)	Treatment	Measures	Results
Salvatore [18]	Postmenopausal women (n = 50)	Fractional CO <sub>2</sub> laser	Vaginal dryness, vaginal burning, vaginal itching, dyspareunia, dysuria Vaginal Health Index (VHI)	At 12-week follow-up, statistically significant improvements in  - VHI score ( $p < 0.001$ ) - Vaginal dryness, burning, itching, dyspareunia, dysuria ( $p < 0.001$ ).
Filippini [23]	Cancer patients and natural menopausal participants (n = 46)	Fractional CO <sub>2</sub> laser	Vaginal burning, vaginal dryness, vaginal itching, dyspareunia, heat, pain	Two months after the first treatment, improvements recorded in  - symptoms of burning, dryness, dyspareunia, itching, heat, and pain (decreases ranged from 73.76% to 88.85%; statistical significance not reported).
Perino [22]	Postmenopausal women (n = 48)	Fractional CO <sub>2</sub> laser	Vaginal dryness, vaginal burning, vaginal itching, dyspareunia VHI	30 days after final laser application, statistically significant improvements in  - VHI score ( $p < 0.0001$ ) - Vaginal dryness, burning, itching, dyspareunia ( $p < 0.0001$ ).
Pieralli [24]	Postmenopausal breast cancer survivors (n = 50)	Fractional CO <sub>2</sub> laser	VHI Dyspareunia	After three sessions, statistically significant improvement in  - dyspareunia ( $p < 0.0001$ ) At thirty days post-treatment, statistically significant improvement in - VHI score ( $p < 0.0001$ ).
Sokol [25]	Women of mean age 58.6 (+/- 8.8 y; n = 30)	Fractional CO <sub>2</sub> laser	Vaginal burning, vaginal dryness, vaginal itching, dyspareunia, dysuria, pain VHI Female Sexual Function Index	At three-month follow-up, improvements in  - vaginal burning, itching, dryness, dyspareunia, dysuria and pain (statistical significance not reported) - VHI score ( $p < 0.001$ ) - Female Sexual Function Index ( $p < 0.001$ ).
Pitsouni [21]	Postmenopausal women (n = 53)	Fractional CO <sub>2</sub> laser	Vaginal Maturation Value (VMV), VHI, sexual function, symptoms of GSM, Female Sexual Function Index (FSFI), International Consultation on Incontinence Questionnaire of Female Urinary Tract Symptoms (ICIQ-FLUTS) and Urinary Incontinence Short Form (ICIQ-UI SF), Urogenital Distress Inventory (UDI-6) and King's Health Questionnaire (KHQ).	At 12 week follow-up, MV, VHIS and FSFI increased significantly. Dyspareunia, dryness, burning, itching, dysuria, frequency, urgency, urgency incontinence, stress incontinence and scores on the ICIQ-FLUTS, ICIQ-UI SF, UDI-6 and KHQ decreased significantly

thermally altering only a fraction of the epidermal and/or dermal architecture, leaving intervening areas unaltered [13]. These intact areas allow for rapid healing of the tissue [13]. Modern fractional microablative CO<sub>2</sub> lasers incorporate trains of very short high peak power pulses with long interpulse intervals; this modification allows for cleaner incision or ablation with less charring because each pulse is shorter than the thermal relaxation time of the target tissue, so that optimum ablation and heat deposition is achieved with minimal heat build-up in the adjacent tissue [14].

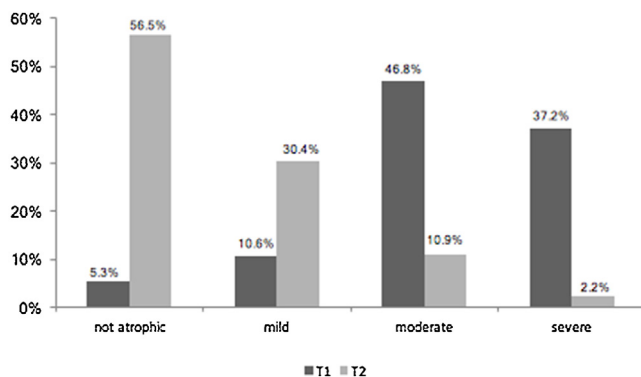
Fractional micro-ablative CO<sub>2</sub> has proved to be safe in remodelling tissue properties of many body regions, such as the skin of the face, neck and chest, and has the ability to produce new collagen and elastic fibres [15]. Within the atrophic vagina, fractional micro-ablative CO<sub>2</sub> treatment has been reported to produce a thicker epithelium along with larger diameter epithelial cells rich in glycogen [16]. Further, this therapy has been shown to increase *Lactobacillus* and reduce vaginal pH [17].

To date, a handful of studies have investigated the short-term effects of fractional CO<sub>2</sub> laser as a treatment for GSM (Table 1). These studies have demonstrated short-term improvements in Vaginal Health Index (VHI) scores, vaginal dryness, burning, itching, dyspareunia and dysuria, generally in postmenopausal samples.

The pilot study of 50 women conducted by Salvatore et al. [18] demonstrated that treatment with fractional CO<sub>2</sub> was feasible, safe and resulted in significant improvement of symptoms related to atrophy at 12 weeks' follow-up. These outcomes are reported to significantly improve overall sexual satisfaction and quality of life [18]. However, no study has assessed the long-term efficacy of fractional CO<sub>2</sub> laser treatment. The purpose of this study was to investigate the safety, feasibility and long-term efficacy (12–24 months) of fractional micro-ablative CO<sub>2</sub> treatment in a cohort of postmenopausal women suffering dyspareunia and/or other symptoms due to GSM. The primary objective focussed on improvement of GSM symptoms and sexual satisfaction. As a secondary end-point, we investigated any potential side-effects associated with the treatment, with a focus on bladder function symptoms of prolapse.

## Materials and methods

Women with symptoms of genitourinary syndrome of menopause (GSM) who were not responding to or not able to take conventional treatments (such as oestrogen therapy for postmenopausal women) were recruited to the study and underwent vaginal treatment with fractional CO<sub>2</sub> laser.



**Fig. 1.** Changes in severity of GSM symptoms between pre-treatment (T1; n = 94) and post-treatment assessment (T2; n = 92). Women were scored for GSM symptom severity pre- and post-treatment. Symptom severity was rated in the following categories: not atrophic, mild atrophy, moderate atrophy, or severe atrophy. The percentage of women in each category is shown.

Inclusion criteria included postmenopausal women aged between 51 and 86 years, and complaint of at least one of the following GSM symptoms: (1) vaginal dryness, and/or (2) dyspareunia. Exclusion criteria included unexplained bleeding, abnormal pap-smear, active genital infections or any kind of active cancer within the urogenital area. Patients undergoing any concomitant treatment throughout the study period were excluded.

At the first consultation, all the women were asked to provide written informed consent for their clinical data to be collected for the purpose of clinical quality study, and where applicable, for scientific presentation and/or publications. They were also asked to complete a validated interviewer-administered pelvic floor questionnaire (the Australian Pelvic Floor Questionnaire) [19] which integrates bladder, bowel, sexual function, pelvic organ prolapse, severity, bothersomeness and condition-specific quality of life, on a scale of 0–3 (see attached survey). A gynecologist (FBW) performed a colposcopy and graded the atrophy according to elasticity, fluid volume, epithelial integrity and moisture as per Bachmann to define atrophy on a modified four-point scale (not atrophic, mild, moderate and severe atrophy).

For analysis of treatment outcomes, intensity of GSM symptoms (vaginal dryness, vaginal dyspareunia, vaginal tightness, prolapse symptoms, bladder function and urge and stress incontinence) was recorded using measures of frequency and severity. Questionnaires were completed anonymously. Nurses collected each questionnaire after completion and labelled it using a random computer-generated enrolment number. Clinical data and the questionnaire were collected at baseline before the first treatment (T1), between 2 and 4 months from initial treatment (T2), and between 12 and 24 months after the initial laser treatment (T3). The study received Human Research Ethics approval from Bellberry Limited (Application ID: 2016-04-293). Patients were not compensated for participation in this study.

## Study protocol

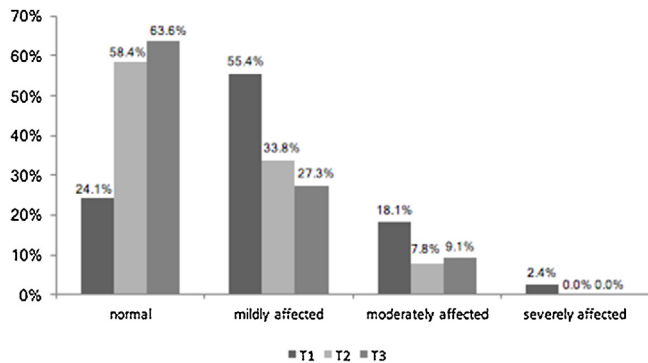
Prior to laser treatment, all patients underwent colposcopy to stage and confirm atrophic vaginitis and to exclude other underlying pathology such as vulvar intraepithelial neoplasia (VIN) and lichen sclerosus. Pelvic ultrasound was carried out at baseline to assess and record endometrial thickness. Patients with a past medical history of genital herpes were given prophylactic antiviral medication. Each participant was treated with the fractional microablative MonaLisa Touch CO<sub>2</sub> laser system (SmartXide2 V<sub>2</sub>LR, DEKA, Italy) with the following settings: power 30 W, dwell time 1000 μs, DOT spacing 1000 μm, SmartStak parameter 2, and D- pulse mode. The laser beam was emitted after the vaginal probe was inserted to the top of the vaginal canal, then rotated and withdrawn in order to provide complete 360° coverage of the vaginal wall. The vestibule and fourchette were treated with a 90° probe, with the following settings: power 20 W, dwell time 1000 μs, DOT spacing 1000 μm, SmartStak parameter 1, and D-pulse mode.

A silicon-based balm was used post-procedure to enhance wound healing and aid hydration of the skin. The balm was not used vaginally; rather, it was applied to the fourchette of the vagina. The balm contained a combination of physiologic lipids and botanical sterols and has been previously shown to reduce post-operative swelling, aid healing and reduce the risk infection following laser treatment [20].

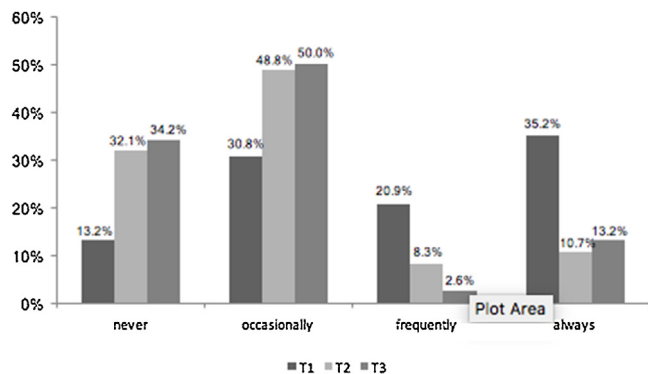
Each patient received three fractional CO<sub>2</sub> vaginal laser treatments at intervals of six or more weeks. Follow-up was approximately 12 months after the initial treatment. The procedure was performed by one gynaecologist. Participants did not require any specific analgesia or anaesthesia. They were advised to

**Table 2**  
Scores on sexual variables at pre-treatment (T1), after the third treatment (T2), and at the 12–24 month follow-up (T3). Changes are represented using Wilcoxon's signed-rank test scores.

	Median scores			Changes							
	T1	T2	T3	Change T1-T2 (improvement% (n), Z, r, p)				Change T1-T3 (improvement% (n), Z, r, p)			
				% (n)	z	r	p	% (n)	z	r	P
Sexual function	1	0	0	62 (66)	-4.66	0.40	<0.001	44 (25)	-2.82	0.39	0.005
Painful intercourse	2	1	1	66 (78)	-5.16	0.41	<0.001	71 (34)	-3.11	0.37	0.002
Sexual issues	2	1	1	50 (85)	-6.04	0.46	<0.001	48 (40)	-4.20	0.47	<0.001



**Fig. 2.** Change in participants' sexual dysfunction scores at pre-treatment (T1; n = 83), after the third treatment (T2; n = 77), and at 12–24 month follow-up (T3; n = 33). Women rated their level of sexual dysfunction in the following categories: normal, mildly affected, moderately affected and severely affected. The percentage of women in each category is shown.



**Fig. 3.** Changes in the frequency of self-reported pain during intercourse at pre-treatment (T1; n = 91), after the third treatment (T2; n = 84), and at 12–24 month follow-up (T3; n = 38). Women rated the frequency of pain during intercourse in the following categories: never, occasionally, frequently, and always. The percentage of women in each category is shown.

avoid vaginal intercourse, bathing, and using the bath for at least 5 days after each laser application, so as to allow tissue healing.

### Statistical analysis

Based on the study by Pitsouni et al. [21] a sample size of 47 participants would be required to achieve 5% significance, 90% power and a hypothetical effect size of 0.5 (medium effect). With the expectation that there would be ~50% attrition from the time of recruitment to follow-up, we needed a minimum of 94 patients enrolled in the study. Wilcoxon signed-rank tests were used to detect any statistically and clinically significant differences occurring from pre- to post-treatment. Statistical significance

was set at 0.05. Data were analyzed using IBM SPSS software, version 21.0 (IBM, New York, NY).

### Results

In this study, we recruited 102 postmenopausal women experiencing symptoms of GSM with an age ranging from 51 to 86 ( $M = 61.00$ ;  $SD = 7.00$ ). All the cases were postmenopausal.

Among women in study, common reasons given for discontinuing oestrogen therapy include (i) local side-effects (e.g. irritation, a sensation of burning), (ii) a desire to find out whether climacteric symptoms have ended, (iii) fear of breast cancer and (iv) fear of thrombo-embolism.

#### Changes in severity of GSM symptoms

Approximately 84% of the patients who suffered from moderate or severe GSM experienced an improvement in symptoms, moving into the 'mild' or 'not atrophic' categories following treatment (Fig. 1). A Wilcoxon signed-rank test revealed a statistically significant improvement in GSM symptoms following participation in treatment,  $z = -7.75$ ,  $p < 0.001$ , with a large effect size ( $r = 0.57$ ). The median severity score decreased from pre-treatment ( $Md = 2$ ) to post-treatment ( $Md = 0$ ).

#### Sexual function

Median scores on sexual function variables at pre-treatment (T1), after third treatment (T2; 2–4 months after initial treatment), and at 12–24 month follow-up (T3) are shown in Table 2. Due to patient attrition, sample sizes are reported for each time-point. There were statistically significant improvements for all variables assessed, including scores on sexual function, painful intercourse, and other sexual issues including vaginal dryness and reduced libido.

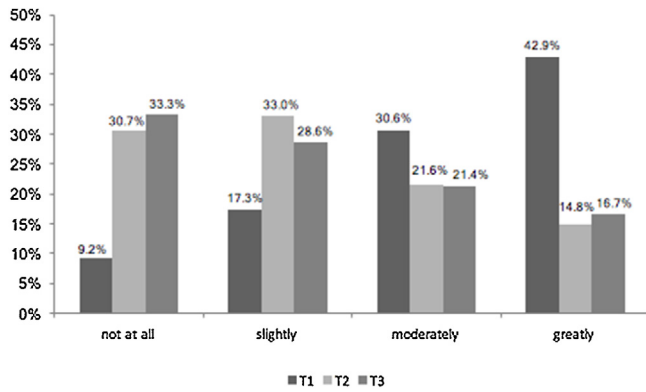
There was an overall reduction in the participants' sexual dysfunction scores from T1 to T2, with an increase in the number of patients reporting "normal" sexual functioning from 24.1% at T1 to 58.4% at T2 (Fig. 2). This trend remained stable (63.6%) at T3 (12–24 month follow-up). The percentage of participants reporting mild, moderate and severe sexual dysfunction tended downwards from T1 to T3 (insert data?).

There was an overall improvement in participants' self-reported pain during intercourse (i.e. dyspareunia; Fig. 3), with an increase from 13.2% at T1 to 32.1% at T2 in the percentage of participants who self-reported "never" experiencing painful intercourse. The trend remained stable (34.2%) at T3.

This trend was mirrored by the percentage of participants self-reporting "bother" with sexual intercourse issues (Fig. 4).

#### Secondary effects

While the focus of the study was on GSM and sexual function, we also investigated several effects of the laser treatment among



**Fig. 4.** Extent to which patients reported that sexual issues were bothering them at pre-treatment (T1; n=98), after the third treatment (T2; n=88), and at 12–24 month follow-up (T3; n=42). Women rated how bothersome sexual issues were according to the following categories: not at all, slightly, moderately or greatly. The percentage of women in each category is shown.

women with urinary incontinence issues or prolapse. Other variables from the Australian Pelvic Floor Questionnaire were analysed using Wilcoxon’s signed-rank test (Table 3). There were significant improvements from T1 to T2 on indices of prolapse, vaginal sensation, vaginal lubrication, bladder function, and urge incontinence. These improvements were also observed at T3.

We observed complications in a small number of patients. Following treatment, three women experienced post-coital urinary tract infections and two experienced vaginal discharge/infection; all of them required antibiotic treatment. Three women experienced lower pelvic pain for two to three days, and required simple analgesia (such as ibuprofen). One patient (who had failed to inform us about her past medical history of genital herpes) had a genital herpes breakout following treatment. Finally, two women presented with postmenopausal bleeding following their third laser treatment (at 4 months and 6 months respectively). Investigation of the endometrial thickness revealed an increase in their endometrium from 3 mm to 5 mm. Their endometrial biopsies were benign. The increase in endometrial thickness may be coincident, or may be related to revitalisation and rejuvenation occurring beyond the vagina following laser treatment.

**Discussion**

Fractional CO<sub>2</sub> laser treatment has displayed a good safety profile [13,22] though there is a need for larger-scale studies to assess the risk/benefit profile of this treatment in patients with GSM [18]. This study is the first to assess the long-term effects of fractional microablative CO<sub>2</sub> laser treatment on GSM symptoms, sexual function, bladder-related issues, and prolapse in postmenopausal women who had failed to respond to oestrogen therapy. Previous pilot studies of fractional microablative CO<sub>2</sub> laser in GSM patients have tended to adopt the Vaginal Health Index (VHI) and/or a Visual Analogue Scale (VAS) to measure symptom intensity.

To the best of our knowledge, this is the first study of its kind to employ the Australian Pelvic Floor Questionnaire, to record changes in general bladder function, sexual function, urge incontinence and prolapse following fractional microablative CO<sub>2</sub> treatment.

In the short term (2–4 months after the initial treatment), we observed significant improvements in sexual function, dyspareunia, sexual issues, bladder function, prolapse symptoms, vaginal sensation and lubrication, and urge incontinence. From baseline to long-term follow-up (between 12 and 24 months), we recorded statistically significant improvements in all above mentioned variables. This indicates that the improvements observed in the short term were maintained at long-term follow-up.

It is likely that these positive effects observed at follow-up in postmenopausal women were due to the alleviation of urogenital symptoms and the restoration of genital tissue viability. Our current data provide evidence for the efficacy of fractional microablative CO<sub>2</sub> laser treatment in improving symptoms associated with GSM and quality of life at short- and long-term follow-up. These results are consistent with those of Salvatore et al. [18], Filippini & Farinelli [23], Perino et al. [22], Pieralli et al. [24], and Sokol et al. [25]. The size of the cohort within this study adds strength to the findings, and the long-term follow up demonstrates long-term efficacy of this therapy [18,22–25]. To the best of our knowledge, this is the first study of its kind to be completed in Australia.

The high rate of women with improved sexual function as well as the reduction in pain and irritation experienced by patients following intercourse further supports the use of fractional microablative CO<sub>2</sub> laser as a treatment for GSM in postmenopausal women. Specific factors related to sexual function, such as vaginal lubrication and vaginal tightness, improved following treatment. This demonstrates the multi-modal ability of this technique to treat a wide range of symptoms. Although not the primary outcome of this study, the improvement in prolapse symptoms, impaired bladder function, urge and stress incontinence were interesting outcomes of this study. It is possible that fractional microablative CO<sub>2</sub> laser is also improving the general comfort and self-confidence of patients, thus further contributing to their enhanced sexual function.

One limitation of our study was the high attrition rate; participant responses decreased by less than half from the third treatment to the 12–24 month follow-up, making it difficult to be confident in the soundness of comparisons from baseline to the final follow-up. However, we recruited a larger number of participants than previous studies in anticipation of patient attrition during follow-up. Another weakness of this study is the absence of a control group receiving either a placebo or hormonal treatment. However, these data combined with the other short-term studies using fractional CO<sub>2</sub> laser treatment provide evidence to warrant a randomised controlled trial. Furthermore, it would be of interest to extend the use of fractional CO<sub>2</sub> lasers to women with severe contraindications to hormonal treatments, such as cancer survivors who lack long-term safety data for hormonal therapy.

**Table 3**  
Description of positive side-effects at pre-treatment (T1), after the third treatment (T2), and at the 12–24 month follow-up (T3).

	Median scores			Changes							
	T1	T2	T3	Change T1-T2 (improvement% (n), Z, r, p)				Change T1-T3 (improvement% (n), Z, r, p)			
				% (n)	z	r	p	% (n)	z	r	p
Prolapse symptoms	0	0	0	69 (86)	-3.26	0.25	0.001	82 (38)	-3.08	0.36	0.002
Vaginal sensation	0	0	0	61 (96)	-3.24	0.23	0.001	63 (46)	-2.69	0.28	0.007
Vaginal lubrication	1	0	0	26(78)	-3.90	0.31	<0.001	36 (34)	-2.53	0.34	0.011
Bladder function	0	0	0	77 (74)	-3.27	0.27	0.001	77 (39)	-2.17	0.25	0.029
Urge incontinence	1	0	0	51 (97)	-2.92	0.29	0.003	53 (48)	-3.64	0.37	0.000

Nevertheless, this study demonstrates that fractional CO<sub>2</sub> laser treatment can provide long-term improvements in the GSM symptoms for postmenopausal women, and these data combined with the other short-term studies using fractional CO<sub>2</sub> laser treatment provide sufficient evidence to warrant a randomised controlled trial. The results of this study are encouraging in that women with age-related GSM who are normally unresponsive to oestrogen therapy experienced noticeable improvements in their sexual function, dyspareunia and the overall severity of symptoms associated with this condition.

In conclusion, the present study demonstrates that fractional micro-ablative CO<sub>2</sub> laser promises to offer an effective, safe and non-invasive treatment alternative for GSM, with improvements in sexual function, reduced symptoms of dyspareunia following intercourse and an overall satisfaction with sexual life in postmenopausal women suffering from GSM. This study adds to the current literature by providing pioneering evidence into the long-term effects of ongoing treatment with fractional micro-ablative CO<sub>2</sub> lasers. The results of this study are encouraging in that they present an alternative treatment to topical estrogen in women who are nonresponsive and/or noncompliant, as well as women who have been advised not to use E2 or those high-risk women who are worried about possible side effects.

## Disclosures

The authors have no conflict of interest. FBW is a preceptor for Monalisa and runs laser workshops for the company. FBW is paid to run these teaching workshops but received no support, financial or otherwise, to run this study.

## Funding

There were no sources of funding for this study.

## Acknowledgement

Dr. Alison Care is supported by fellowship grants from the National Health and Medical Research Council of Australia (APP1092191).

## Appendix A. Supplementary data

Supplementary data associated with this article can be found, in the online version, at <http://dx.doi.org/10.1016/j.ejogrb.2017.03.036>.

## References

- [1] Castelo-Branco C, Cancelo MJ, Villero J, Nohales F, Julia MD. Management of post-menopausal vaginal atrophy and atrophic vaginitis. *Maturitas* 2005;52 (Suppl. 1):S46–52.
- [2] Kingsberg SA, Kellogg S, Krychman M. Treating dyspareunia caused by vaginal atrophy: a review of treatment options using vaginal estrogen therapy. *Int J Womens Health* 2009;1:105–11.
- [3] Portman DJ, Gass ML. Genitourinary syndrome of menopause: new terminology for vulvovaginal atrophy from the International Society for the Study of Women's Sexual Health and the North American Menopause Society. *Menopause* 2014;21:1063–8.
- [4] Salvatore S, Nappi RE, Parma M, Chionna R, Lagona F, Zerbinati N, Ferrero S, Origoni M, Candiani M, Leone Roberti Maggiore U. Sexual function after fractional microablative CO(2) laser in women with vulvovaginal atrophy. *Climacteric* 2015;18:219–25.
- [5] Lachowsky M, Nappi RE. The effects of oestrogen on urogenital health. *Maturitas* 2009;63:149–51.
- [6] Ambler DR, Bieber EJ, Diamond MP. Sexual function in elderly women: a review of current literature. *Rev Obstet Gynecol* 2012;5:16–27.
- [7] Palacios S. Managing urogenital atrophy. *Maturitas* 2009;63:315–8.
- [8] Nappi RE, Polatti F. The use of estrogen therapy in women's sexual functioning (CME). *J Sex Med* 2009;6:603–16 [quiz 18–9].
- [9] Paoletti R, Crosignani PG, Kenemans P, Wenger NK, Jackson AS. Women's health and menopause. Kluwer Academic Publishers; 1999.
- [10] Shulman LP, Portman DJ, Lee WC, Balu S, Joshi AV, Cobden D, Wang Q, Pashos CL. A retrospective managed care claims data analysis of medication adherence to vaginal estrogen therapy: implications for clinical practice. *J Womens Health* (2002) 2008;17:569–78.
- [11] Cardozo L, Lose G, McClish D, Versi E. A systematic review of the effects of estrogens for symptoms suggestive of overactive bladder. *Acta Obstet Gynecol Scand* 2004;83:892–7.
- [12] Fistončić N, Fistončić I, Š. Guštek F, Turina ISB, Marton I, Vižintin Z, Kažič M, Hreljac I, Perhavec T, Lukač M. Minimally invasive, non-ablative Er YAG laser treatment of stress urinary incontinence in women: a pilot study. *Lasers Med Sci* 2016;31:635–43.
- [13] Gotkin RH, Sarnoff DS, Cannarozzo G, Sadick NS, Alexiades-Armenakas M. Ablative skin resurfacing with a novel microablative CO2 laser. *J Drugs Dermatol* 2009;8:138–44.
- [14] Omi T, Numano K. The role of the CO2 laser and fractional CO2 laser in dermatology. *Laser Ther* 2014;23:49–60.
- [15] Hutchinson-Colas J, Segal S. Genitourinary syndrome of menopause and the use of laser therapy. *Maturitas* 2015;82:342–5.
- [16] Use of CO2 laser therapy against vaginal atrophy, vaginal laxity and urinary incontinence.. at [http://www.monalisatouch.com/wp-content/uploads/2015/03/SX2\\_V2LR\\_Salvatore\\_et\\_al\\_DekaWP\\_Jul2013.eng\\_rev1\\_3.pdf](http://www.monalisatouch.com/wp-content/uploads/2015/03/SX2_V2LR_Salvatore_et_al_DekaWP_Jul2013.eng_rev1_3.pdf)..
- [17] Athanasiou S, Pitsouni E, Antonopoulou S, Athanasiou S, Pitsouni E, Antonopoulou S, Zacharakis D, Salvatore S, Falagas ME, Grigoriadis T. The effect of microablative fractional CO2 laser on vaginal flora of postmenopausal women. *Climacteric* 2016;19:512–8.
- [18] Salvatore S, Nappi RE, Zerbinati N, Calligaro A, Ferrero S, Origoni M, Candiani M, Leone Roberti Maggiore U. A 12-week treatment with fractional CO2 laser for vulvovaginal atrophy: a pilot study. *Climacteric* 2014;17:363–9.
- [19] Baessler K, O'Neill SM, Maher CF, Battistutta D. Australian pelvic floor questionnaire: a validated interviewer-administered pelvic floor questionnaire for routine clinic and research. *Int Urogynecol J Pelvic Floor Dysfunct* 2009;20:149–58.
- [20] Batra RS, Ort RJ, Jacob C, Hobbs L, Arndt KA, Dover JS. Evaluation of a silicone occlusive dressing after laser skin resurfacing. *Arch Dermatol* 2001;137:1317–21.
- [21] Pitsouni E, Grigoriadis T, Tsiveleka A, Zacharakis D, Salvatore S, Athanasiou S. Microablative fractional CO2-laser therapy and the genitourinary syndrome of menopause: an observational study. *Maturitas* 2016;94:131–6.
- [22] Calligaro A, Forlani F, Tiberio C, Cucinella G, Svelato A, Saitta S, Calagna G. Vulvo-vaginal atrophy: a new treatment modality using thermo-ablative fractional CO2 laser. *Maturitas* 2015;80:296–301.
- [23] Filippini M, Farinelli M. Use of the MonaLisa Touch treatment on cancer patients. Republic of San Marino: State Hospital – Republic of San Marino; 2014.
- [24] Pieralli A, Fallani MG, Becorpi A, Bianchi C, Corioni S, Longinotti M, Tredici Z, Guaschino S. Fractional CO2 laser for vulvovaginal atrophy (VVA) dyspareunia relief in breast cancer survivors. *Arch Gynecol Obstet* 2016;294:841–6.
- [25] Sokol ER, Karram MM. An assessment of the safety and efficacy of a fractional CO2 laser system for the treatment of vulvovaginal atrophy. *Menopause* 2016;23:1102–7.