

# Fractional microablative CO<sub>2</sub> laser for vulvovaginal atrophy in women treated with chemotherapy and/or hormonal therapy for breast cancer: a retrospective study

Tiziana Pagano, MD,<sup>1</sup> Pasquale De Rosa, MD,<sup>1</sup> Roberta Vallone, MD,<sup>1</sup> Francesco Schettini, MD,<sup>2</sup> Grazia Arpino, MD, PhD,<sup>2</sup> Sabino De Placido, MD, PhD,<sup>2</sup> Giovanni Nazzaro, MD, PhD,<sup>1</sup> Mariavittoria Locci, MD,<sup>1</sup> and Giuseppe De Placido, MD<sup>1</sup>

---

## Abstract

**Objectives:** Breast cancer is one of the most common malignancies in women. Hormonal treatment and chemotherapy induce a transient or permanent menopause status. Vulvovaginal atrophy (VVA) is a frequent debilitating symptom of menopause that is best treated with local or systemic estrogen formulations. Because estrogens drive the growth of the majority of breast cancers, most effective VVA therapies are precluded. The aim of this study was to evaluate the effects of fractional microablative CO<sub>2</sub> laser on sexual function and in relieving symptoms in women with breast cancer and VVA induced or exacerbated by iatrogenic menopause.

**Methods:** This retrospective study included 26 women affected by hormone-receptor positive breast tumors and treated for VVA symptoms with the fractional microablative CO<sub>2</sub> laser system. Every 30 to 40 days, women underwent a cycle of treatment for a total of three cycles. During each cycle, women underwent a gynecological examination and completed visual analog scale questionnaires designed to assess (1) the degree of symptoms and (2) procedure-related discomfort.

**Results:** Treatment resulted in a significant regression of VVA symptoms and procedure-related discomfort versus baseline ( $P < 0.001$  in almost all cases). No adverse reactions were observed nor reported by women.

**Conclusions:** Fractional microablative CO<sub>2</sub> laser treatment is associated with a significant improvement of VVA symptoms in women affected by hormone-driven breast cancer. This procedure has the advantage of relieving iatrogenic/physiological VVA symptoms without resorting to contraindicated estrogen preparations, which have been the most effective therapy thus far.

**Key Words:** Breast cancer – CO<sub>2</sub> laser therapy – Estrogen preparations – Hormone receptors – Vulvovaginal atrophy.

---

**B**reast cancer is the most common malignant tumor in women with an incidence between 27/100,000 (Central Africa) and 96/100,000 (Western Europe) cases. It is estimated that approximately 12.3% of women will be diagnosed with breast cancer at some point during their lifetime, with an incidence peak between the ages of 55 and 64 years. An early diagnosis through mammographic screening and improvements in adjuvant systemic therapies

has significantly improved cancer survival so that the percentage of women with breast cancer alive 5 years after diagnosis is currently around 90%.<sup>1</sup> Hormonal treatment such as GnRH analogues, tamoxifen and aromatase inhibitors, and chemotherapy are the current standard therapeutic approaches, together with surgery and radiotherapy, depending on cancer features, stage at diagnosis, and possible contraindications. Chemotherapy and antiestrogenic endocrine compounds may induce a reversible or irreversible menopause status.<sup>2</sup> This is an issue that physicians are encountering more frequently because the percentage of young women diagnosed with breast cancer is increasing albeit slightly. Currently, around 11% of all newly diagnosed breast tumors affect women under the age of 44 years.<sup>1</sup> One of the most bothersome problems during both physiological and therapy-induced menopause is vulvovaginal atrophy (VVA) that women usually do not report to their oncologist. This condition is a direct consequence of estrogen-deprivation that causes morpho-functional changes in vulvar and vaginal tissues: the vaginal epithelium becomes pale, thin and dry, and easily becomes infected. Also the skin of the labia minora

---

Received January 28, 2016; revised and accepted March 8, 2016.

From the <sup>1</sup>Reproductive Medicine Unit, Department of Neuroscience, Reproductive Medicine, Odontostomatology, and <sup>2</sup>Medical Oncology, Department of Clinical and Surgical Medicine, University of Naples "Federico II", Naples, Italy.

All authors conceived the study. R.V., P.D.R., and T.P. performed the laser technique and collected data. F.S., P.D.R., R.V., and T.P. wrote the article. F.S. performed the statistical analyses. All authors revised and approved the final article.

Funding/support: None.

Financial disclosure/conflicts of interest: None reported.

Address correspondence to: Francesco Schettini, MD, Medical Oncology, Department of Clinical and Surgical Medicine, University of Naples "Federico II", Via Sergio Pansini 5, Naples 80131, Italy.  
E-mail: francescoschettini1987@gmail.com

and vestibule becomes pale, thin and dry, and the fat contained in the labia majora decreases. As a result, VVA often leads to vaginal dryness, itching/stinging and bleeding, and to dyspareunia and dysuria.<sup>3</sup> All of these symptoms reduce the quality of life also in breast cancer survivors, particularly in younger ones without menopausal symptoms. In fact, in a cohort of breast cancer survivors, vaginal dryness was present in 23.4% of premenopausal women.<sup>4</sup>

Treatment of VVA depends on the physician's clinical experience and the patient's preference.<sup>5</sup> Various treatments are available, for example, vaginal or systemic estrogens; moisturizers; silicon-, oil-, or water-based lubricants; vaginal dilators; vaginal vitamin E; oral vitamin D; smoking cessation; phytoestrogen formulations; and ozonized oil/creams. Among these, vaginal or systemic estrogen formulations were the most effective in a meta-analysis of 19 randomized clinical trials involving more than 4,000 postmenopausal women.<sup>5</sup> Systemic estrogen formulations are, however, contraindicated in breast cancer patients. Moreover, in a small study, blood estrogen levels were slightly increased in seven breast cancer survivors undergoing aromatase inhibitor therapy after 2 weeks of treatment with local estrogen formulations.<sup>6</sup> Therefore, given the concern about the safety of vaginal estrogens, this treatment is not indicated in breast cancer patients with VVA.<sup>6</sup> Nonhormonal treatments such as water-based vaginal moisturizers, water- or silicon-based lubricants, have a short activity and may interfere with the partner's erectile functions. Complementary and alternative medical products have either not been evaluated in controlled trials or are simply not effective.<sup>5</sup>

Fractional microablative CO<sub>2</sub> laser is a relatively recent technique, originally tested for the treatment of acne scars, resurfacing of the neck, and skin rejuvenation.<sup>7-9</sup> It seems to produce new collagen and elastic fibers, and to remodel connective tissues without damaging the surrounding structures.<sup>10</sup> Fractional microablative CO<sub>2</sub> laser significantly improved such VVA symptoms as secondary vaginismus, pain during intercourse, and noncoital pain in postmenopausal women, and it also improved sexual function and overall satisfaction with sexual life.<sup>11-13</sup>

In this scenario, we evaluated the efficacy and safety of the CO<sub>2</sub> laser technique in the clinical setting of women with VVA undergoing chemotherapy and/or hormonal therapy for estrogen-dependent breast cancer, for which no effective approaches are yet available. We also evaluated the participant's satisfaction with the overall procedure.

## METHODS

### Population characteristics and treatment

In this observational retrospective study, we enrolled 26 women aged between 20 and 62 years (median: 42 y) affected by breast cancer attending the Reproductive Medicine Unit (University of Naples "Federico II"), from April 2015 to August 2015. Given its observational and retrospective nature, Ethics Committee approval was not required under Italian law. All women were affected by hormone-receptor

positive breast cancer and had undergone surgery. Only one woman (aged 62 y) was postmenopausal before starting chemo/hormone therapy for breast cancer. Twenty-two women (85%) received adjuvant chemotherapy. The postmenopausal woman was undergoing adjuvant antiestrogen therapy with an aromatase inhibitor (anastrozole), whereas the 25 nonmenopausal women were taking tamoxifen associated with acetate leuprolide or triptorelin to induce a menopause status. All of the women had VVA symptoms due to chemotherapy/hormonal therapy-related menopause. The VVA symptoms in the postmenopausal woman were exacerbated by systemic anticancer treatment. Women were required to discontinue previous VVA treatment at least 30 days before starting the new treatment.

Women underwent three fractional microablative CO<sub>2</sub> laser cycles every 30 to 40 days. A basal gynecological clinical examination and Papanicolaou (PAP) test were performed during the first cycle. The severity of VVA symptoms was assessed with a visual analog scale (VAS) based on a score from 0 to 10, where 0 indicates "absence of symptoms" and 10 indicates a symptom "as bad as it could be." Procedure-related discomfort was assessed with a VAS based on a 0 to 100 score, where 0 indicates "no discomfort" and 100 indicates discomfort "as bad as it could be."<sup>12</sup> The following VVA symptoms were evaluated: vaginal laxity, reduced sensitivity during sexual intercourse, vaginal flatulence and/or leukorrhea, dryness, itching and/or stinging, bleeding, dyspareunia, and dysuria. Procedure-related discomfort was assessed based on the discomfort experienced during the insertion and manipulation of the laser probe, and laser-associated discomfort.

At the second and third cycles and 30 days after the latter, women underwent a gynecological clinical examination, and a reassessment of VVA symptoms and of the degree of procedure-related discomfort via the above-mentioned VAS scales. All PAP tests had to be negative for malignancies or premalignancies. The fractional microablative CO<sub>2</sub> laser (SmartXide<sup>2</sup> V<sup>2</sup>LR, MonaLisa Touch, DEKA, Florence, Italy) procedure was performed as reported elsewhere<sup>11</sup> using the following settings: dot power of 30 V, scan time of 1,000 μs, dot spacing of 1,000 μm, and the Smart Stack parameter from 1 to 3. The procedure did not require any preparation (eg, analgesia/anesthesia). Three gynecologists with same level of skill performed the procedure using the same technique.

## STATISTICAL ANALYSES

The VAS score distribution for each symptom was tested for normality with the Shapiro-Wilk test.<sup>14</sup> No values were distributed normally. Range intervals for all VAS values and respective medians were calculated at baseline (T<sub>0</sub>), and after the first (T<sub>1</sub>), second (T<sub>2</sub>), and third (T<sub>3</sub>) laser cycles. We used the Friedman test<sup>15</sup> to validate the statistical significance of median variations of VAS scores throughout the treatment period. Results were considered statistically significant at  $P < 0.05$ . We also conducted post hoc analyses with separate

Wilcoxon signed-rank tests,<sup>16</sup> and the Bonferroni adjustment<sup>17</sup> was calculated to establish the level of significance. Statistical analyses were performed with the IBM SPSS Statistics software for MAC OSX, version 22.

## RESULTS

All of the basal PAP tests were negative. Fifteen percent of women (4 women) experienced symptomatic vaginal laxity (described as ‘‘a sense of heaviness’’), 77% (20 women) reduced sensitivity during sexual intercourse, 58% (15 women) vaginal flatulence and/or leukorrhea, 65% (17 women) vaginal bleeding, and 58% (15 women) dysuria, although all women reported dryness, itching/stinging and dyspareunia. The range and median VAS scores for VVA symptoms at T0, 1, 2, and 3 and technique-related symptoms at cycle (C) 1, 2, and 3 are reported in Table 1. After three cycles of laser treatment, the median VAS scores for dyspareunia, dryness, itching/stinging, and sensitivity during sexual intercourse were 78%, 80%, 75% and 86%, respectively, lower than baseline. Moreover, the median VAS scores for dysuria, and vaginal bleeding and flatulence/leukorrhea, were 100% lower after treatment. The median VAS scores for vaginal laxity-related symptoms did not differ significantly from T0 to T3 at the Friedman test ( $X^2(3) = 1.326$ ,  $P = 0.723$ ). On the contrary, between T0 and T3, there were significant differences in the median VAS scores of vaginal itching/stinging ( $X^2(3) = 49.004$ ,  $P < 0.0001$ , Fig. 1A), vaginal bleeding ( $X^2(3) = 20.006$ ,  $P < 0.0001$ , Fig. 1B), vaginal flatulence/leukorrhea ( $X^2(3) = 21.326$ ,  $P < 0.0001$ , Fig. 1C), and vaginal dryness ( $X^2(3) = 64.568$ ,  $P < 0.0001$ , Fig. 1D). Last, significant differences were found in the median VAS scores for reduced sensitivity during sexual intercourse ( $X^2(3) = 29.203$ ,  $P < 0.0001$ , Fig. 2A), dyspareunia ( $X^2(3) = 41.838$ ,  $P < 0.0001$ , Fig. 2B), and for dysuria ( $X^2(3) = 11.842$ ,  $P < 0.008$ , Fig. 2C). Post hoc analysis with the Wilcoxon signed-rank test conducted with Bonferroni correction resulted in a significance level of  $P < 0.0083$ . The analyses did not reveal significant statistical differences

between time points in any case; however, significant differences were found between T0 and T3 for almost all symptoms, namely reduced sensitivity during sexual intercourse ( $Z = -3.871$ ,  $P < 0.0001$ ), vaginal flatulence/leukorrhea ( $Z = -3.535$ ,  $P < 0.0001$ ), vaginal dryness ( $Z = -4.47$ ,  $P < 0.0001$ ), vaginal itching/sting ( $Z = -4.265$ ,  $P < 0.0001$ ), vaginal bleeding ( $Z = -3.468$ ,  $P < 0.001$ ), and dyspareunia ( $Z = -3.871$ ,  $P = 0.001$ ), except for dysuria ( $Z = -2.451$ ;  $P = 0.014$ ).

Regarding tolerability of the technique, the median VAS score for intensity of discomfort during insertion of the probe, during probe movements, and for laser-associated pain was 67%, 50% and 30%, respectively, lower after treatment. The differences were statistically significant at the Friedman test for discomfort induced by probe insertion ( $X^2(2) = 10.047$ ,  $P < 0.007$ , Fig. 3A), laser-associated pain ( $X^2(2) = 25.167$ ,  $P < 0.0001$ , Fig. 3B), and for discomfort experienced during manipulation of the probe ( $X^2(2) = 21.447$ ,  $P < 0.0001$ , Fig. 3C). Post hoc analysis with Wilcoxon signed-rank tests conducted with Bonferroni correction resulted in a significance level of  $P < 0.0167$ . The difference between C1 and C3 was significant for all the symptoms evaluated, namely, discomfort at probe insertion ( $Z = -3.082$ ,  $P = 0.002$ ), at probe movements ( $Z = -3.456$ ,  $P = 0.001$ ), and laser-related pain ( $Z = -3.285$ ,  $P = 0.001$ ). No adverse reactions were observed at any physical examination nor were reported by the participants.

## DISCUSSION

Given the high survival rate of women with breast cancer, and the increasing incidence of breast cancer in young women, increasingly more women are affected by physiological or chemotherapy/endocrine therapy-induced menopause and its symptoms, such as VVA. This condition significantly affects the quality of life of breast cancer survivors and, what is worse, the most effective therapies for VVA, namely, systemic and local estrogen formulations, are

**TABLE 1.** Technique-related symptoms assessed with visual analog scales

	T0		T1		T2		T3	
	VAS		VAS		VAS		VAS	
VVA symptoms <sup>a</sup>	Range	Median	Range	Median	Range	Median	Range	Median
Vaginal laxity symptoms	0-8	0	0-7	0	0-6	0	0-5	0
Reduced sensitivity during sexual intercourse	0-10	7	0-8	5	0-9	3	0-5	1
Vaginal flatulence and/or leukorrhea	0-9	4	0-10	3	0-5	1	0-5	0
Vaginal dryness	7-10	10	0-10	6	0-7	4	0-5	2
Vaginal itching/ stinging	2-10	8	0-10	5	0-9	3	0-6	2
Vaginal bleeding	0-10	5	0-10	1	0-9	0	0-8	0
Dyspareunia	5-10	9	0-10	6	0-9	4	0-5	2
Dysuria	0-10	5	0-10	3	0-10	1	0-6	0
Technique tolerability symptoms <sup>b</sup>	C1		C2		C3			
Discomfort during probe insertion	5-50	30	0-70	15	0-40	10		
Discomfort during probe movement	5-60	20	5-40	20	0-30	10		
Laser-associated	0-80	15	0-50	10	0-40	10		

T, time; C, cycle; VAS, visual analog scale; VVA, vulvovaginal atrophy.

<sup>a</sup>On a scale from 0 to 10.

<sup>b</sup>On a scale from 0 to 100.

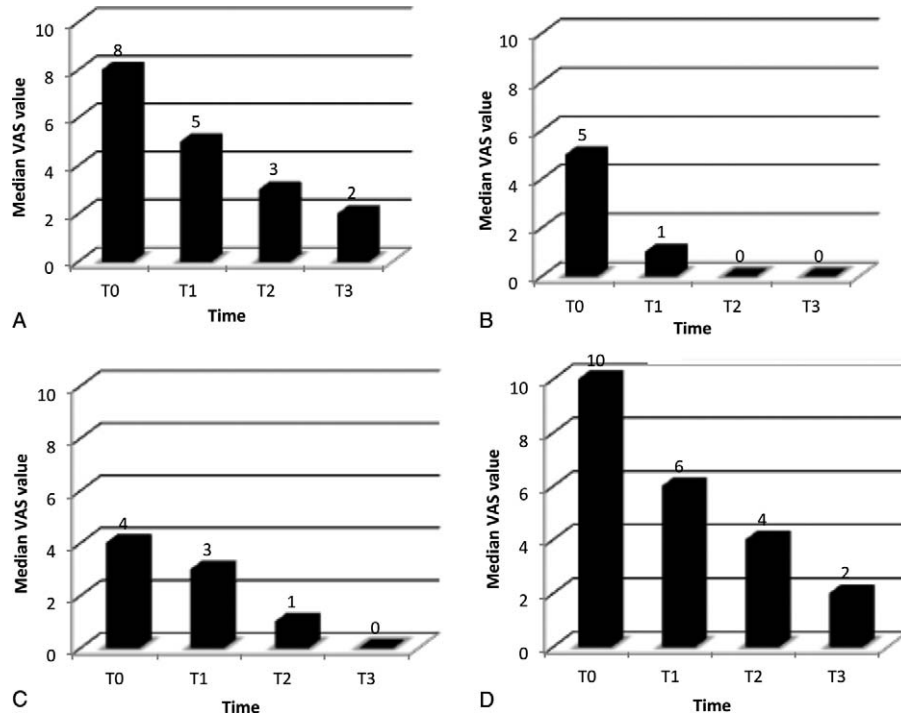


FIG. 1. Median VAS values at different times for vaginal itching/stinging (A), vaginal bleeding (B), vaginal flatulence and/or leukorrhea (C), and vaginal dryness (D). T, time; VAS, visual analog scale.

contraindicated in these women when tumors are estrogen-sensitive. Fractional ablative CO<sub>2</sub> laser is an effective tool for the treatment of VVA in menopause.<sup>10-13</sup> Given its safety, efficacy, and nonestrogen-related mechanism of action, we

evaluated the efficacy of this technique in women with breast cancer suffering from the signs and symptoms of VVA induced or exacerbated by systemic therapies for their breast tumors. Our results confirmed the efficacy of the technique in

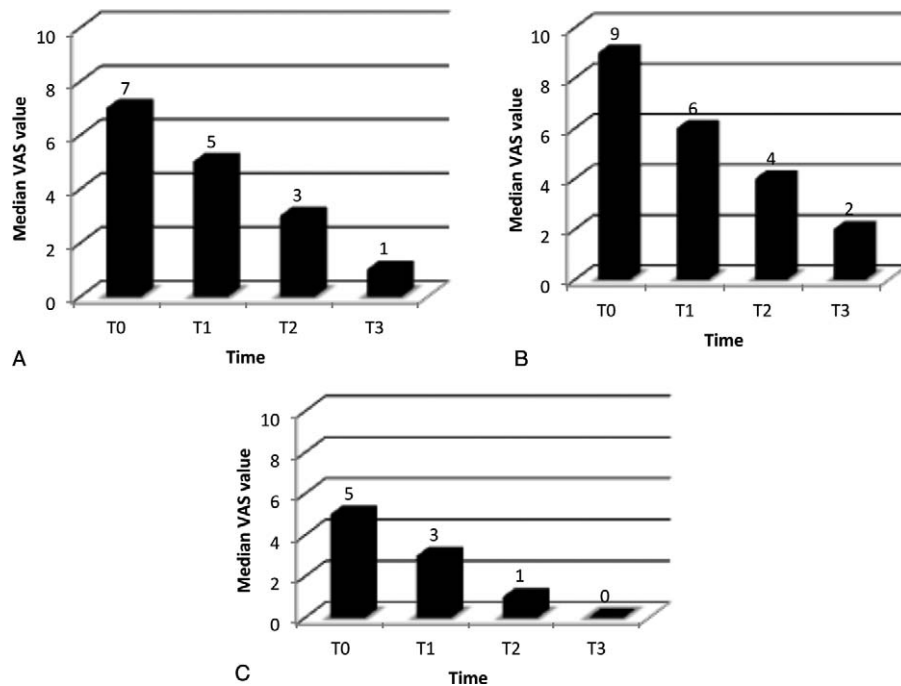
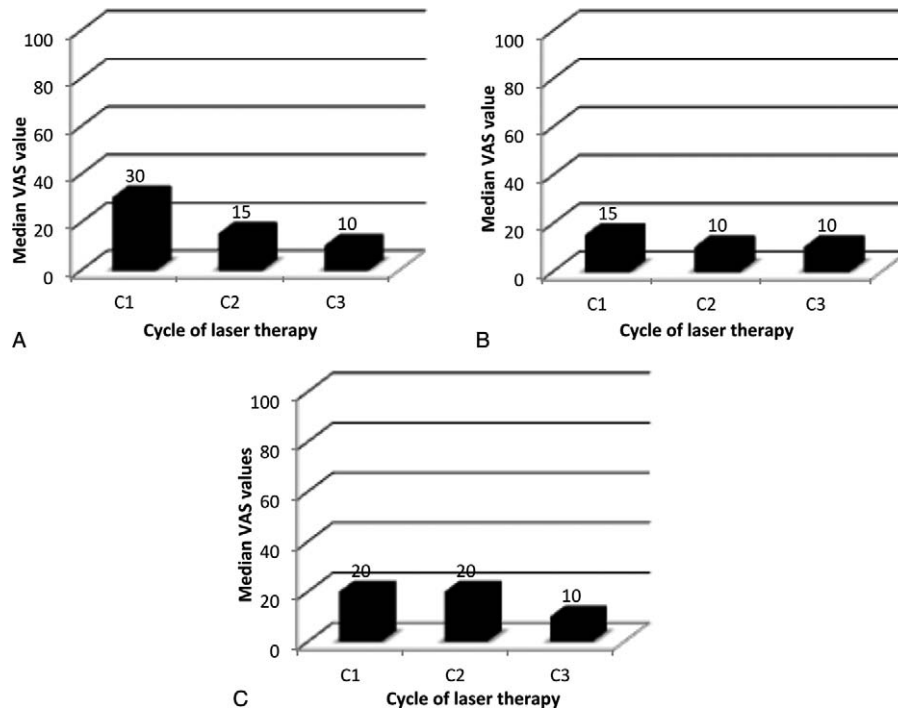


FIG. 2. Median VAS values at different times for reduced sensitivity during sexual intercourse (A), dyspareunia (B), and dysuria (C). T, time; VAS, visual analog scale.



**FIG. 3.** Median VAS values at different times for discomfort experienced during probe insertion (A), laser-associated pain (B), and discomfort associated to probe movements (C). C, cycle; VAS, visual analog scale.

this subset of women. In fact, during the three cycles of laser treatment, the median VAS score for dyspareunia, dryness, and itching/stinging was 78%, 80%, and 75% lower, respectively, whereas dysuria, vaginal bleeding, and vaginal flatulence/leukorrhea were frequently resolved. Also sensitivity during sexual intercourse improved by a median of 86%.

Tolerance to the technique, explored through the evaluation of the intensity of discomfort during insertion of the probe and during probe movements, and laser-associated pain, was better at the end of the three cycles versus baseline, with a reduction in median VAS scores of 67%, 50%, and 30%, respectively. Only vaginal laxity-related symptoms were not significantly improved by the laser technique. It is noteworthy that three VVA symptoms, namely, dysuria, vaginal bleeding, and vaginal flatulence/leukorrhea, were substantially resolved in almost all patients (median VAS scores of 0 and concomitant reduction of score range). The remaining symptoms were also reduced but not resolved, which suggests that more than three cycles may be needed to improve the efficacy of treatment. Efficacy was usually higher at the third cycle of treatment. Specifically, there was a progressive and sustained reduction of the VAS value ranges and medians for almost every parameter. No adverse reactions were observed nor reported by women, consistently with previous studies.<sup>11-12</sup>

### CONCLUSIONS

Our study is the first to explore the potential of fractional microablative CO<sub>2</sub> laser as a therapeutic strategy for VVA induced or worsened by chemotherapy or endocrine therapies

in hormone-receptor positive breast cancer patients, in whom the most effective treatment strategies for VVA symptoms are contraindicated. Our results indicate that this technique is effective and safe in our subset of participants. These findings should be, however, verified in a larger number of patients in a prospective study, preferably comparing the fractional microablative CO<sub>2</sub> laser technology with control arms. Another outstanding issue is to determine the optimal number of treatment cycles. Therefore, studies are needed to evaluate the duration of response and the need for re-treatments. Our study, however, demonstrates the potential of this laser technique as a new effective and safe care for therapy-induced/worsened VVA in women affected by estrogen-driven cancers.

**Acknowledgments:** We thank Jean Ann Gilder (Scientific Communication srl., Naples, Italy) for editing the article.

### REFERENCES

1. Surveillance, Epidemiology and End Results (SEER) Website. Available at: <http://seer.cancer.gov/statfacts/html/breast.html>. Accessed December 2015.
2. Loren AW, Mangu PB, Beck LN, et al. Fertility preservation for patients with cancer: American Society of Clinical Oncology clinical practice guideline update. *J Clin Oncol* 2013;31:2500-2510.
3. Okeke TC, Ezenyeaku CC, Ikeako LC, et al. An overview of vulvovaginal atrophy-related sexual dysfunction in postmenopausal women. *J Basic Clin Reprod Sci* 2012;1:3-8.
4. Crandall C, Petersen L, Ganz PA, et al. Association of breast cancer and its therapy with menopause-related symptoms. *Menopause* 2004;11:519-530.
5. MacBride MB, Rhodes DJ, Shuster LT, et al. Vulvovaginal atrophy. *Mayo Clin Proc* 2010;85:87-94.

6. Kendall A, Dowsett M, Folkard E, et al. Caution: vaginal estradiol appears to be contraindicated in post-menopausal women on adjuvant aromatase inhibitors. *Ann Oncol* 2006;17:584-587.
7. Ong MW, Bashir SJ. Fractional laser resurfacing for acne scars: a review. *Br J Dermatol* 2012;166:1160-1169.
8. Tierney EP, Hanke CW. Ablative fractionated CO<sub>2</sub> laser resurfacing for the neck: prospective study and review of the literature. *J Drugs Dermatol* 2009;8:723-731.
9. Peterson JD, Goldman MP. Rejuvenation of the aging chest: a review and our experience. *Dermatol Surg* 2011;37:555-571.
10. Salvatore S, Leone Roberti Maggiore U, Athanasiou S, et al. Histological study on the effects of microablative fractional CO<sub>2</sub> laser on atrophic vaginal tissue: an ex vivo study. *Menopause* 2015;22:845-849.
11. Perino A, Calligaro A, Forlani F, et al. Vulvo-vaginal atrophy: a new treatment modality using thermo-ablative fractional CO<sub>2</sub> laser. *Maturitas* 2015;80:296-301.
12. Salvatore S, Nappi RE, Zerbinati N, et al. A 12-week treatment with fractional CO<sub>2</sub> laser for vulvovaginal atrophy: a pilot study. *Climacteric* 2014;17:363-369.
13. Salvatore S, Nappi RE, Parma M, et al. Sexual function after fractional microablative CO<sub>2</sub> laser in women with vulvovaginal atrophy. *Climacteric* 2015;18:219-225.
14. Shapiro SS, Wilk MB. An analysis of variance test for normality (complete samples). *Biometrika* 1965;52:591-611.
15. Friedman M. The use of ranks to avoid the assumption of normality implicit in the analysis of variance. *J Am Stat Ass* 1937;32:675-701.
16. Wilcoxon F. Individual comparisons by ranking methods. *Biometrics Bull* 1945;1:80-83.
17. Abdi H. Bonferroni and Šidák corrections for multiple comparisons. In: Salkind NJ, ed. *Encyclopedia of Measurement and Statistics*. Thousand Oaks, CA: Sage; 2007.