


Long-term reliability of fractioned CO₂ laser as a treatment for vulvovaginal atrophy (VVA) symptoms

Annalisa Pieralli¹  · Claudia Bianchi¹ · Manuela Longinotti¹ · Serena Corioni¹ · Noemi Auzzi¹ · Angelamaria Becorpi¹ · Maria Grazia Fallani¹ · Giuseppe Cariti¹ · Felice Petraglia¹

Received: 27 April 2017 / Accepted: 23 August 2017
© Springer-Verlag GmbH Germany 2017

Abstract

Purpose The aim of this study was to evaluate long-term effects of the fractional CO₂ laser for the treatment of vulvovaginal atrophy (VVA) symptoms.

Methods Women presenting with VVA symptoms and meeting inclusion criterion were enrolled to fractioned CO₂ laser therapy. Patient's satisfaction was measured on five-point Likert scale at 4 weeks and 6, 12, 18, 24 months after treatment by interview and clinical examination for vaginal livability.

Results 184 patients constituted the final study group: 128 women were spontaneous menopause and 56 were oncological menopause. 117 women were nulliparous and 36 had previous hysterectomy. 95.4% (172/184) of the patients declared that they were satisfied or very satisfied with the procedure at 4 weeks after treatment. At 6 months 92% (170/184) patients were satisfied; at 12 months 72% (118/162) were satisfied; at 18 months 63% (60/94) were satisfied; at 24 months 25% (4/16) of patients answered they were still satisfied. We observed a decline in patient's satisfaction between 18 and 24 months after laser therapy. Data showed that the time interval from onset of menopause was a statistically significant factor ($p < 0.05$) for treatment satisfaction in oncological group.

Conclusion Long-term data showed that the improvement of vaginal health may continue up to 24 months after fractional CO₂ laser treatment although between 18 and 24 months benefits decline, and approximately 80%

of women decide to start a new treatment cycle of laser applications.

Keywords Vulvovaginal atrophy · Laser · Oncological menopause · Spontaneous menopause · Follow-up

Introduction

Vulvovaginal (VVA) symptoms encompass all symptoms that women may have in the genital areas from loss of estrogen that occurs with the menopause. VVA symptoms include dryness, burning, itching, pain, dyspareunia [1].

VVA is a condition that left untreated can progress and negatively affect quality of life and sexual function. Several therapeutic options are available to alleviate VVA symptoms including both hormonal and non-hormonal interventions. First-line treatments are non-hormonal vaginal moisturizers and lubricants. If these preparations do not provide adequate alleviation of symptoms, estrogen therapy may be used for women with no contraindications to hormonal therapy [2].

In women with persistent symptoms related to VVA, the first-line of pharmacologic treatment are local low-dose estrogen preparations [3].

Local estrogen therapy has several effects on the vulvovaginal tissue including increased secretions, blood flow, thickness of the vaginal epithelium and reduced vaginal pH [4]. The dose, duration of treatment and methods of administration (cream, insert or vaginal ring) needed to improve symptoms vary across patients and should be individualized. In patients with a history of hormone-dependent cancer, the use of vaginal hormone products are contraindicated.

Ospemifene, a tissue-selective estrogen receptor modulator (SERM), was approved for the treatment of VVA. It has estrogenic effect on the vaginal epithelium, improving

✉ Annalisa Pieralli
clbianchi85@gmail.com

¹ Section of Oncological Gynecology, Department of Woman and Child Health, Careggi University Hospital, Largo Brambilla 3, 50134 Florence, Italy

vaginal health and neutral effects on endometrium or breast, and was not associated with risk of thromboembolism. Clinical trials and even long-term studies on breast cancer effects support ospemifene overall safety. Therefore, this pharmacologic therapy represents a valuable tool for women who suffer from VVA, and are afraid of or cannot use local estrogens. The disadvantage of ospemifene is need for oral use at a dose of 30–60 mg daily to achieve therapeutic effects on the vaginal epithelium [5].

Laser therapy is a new non-hormonal intervention for management of VVA. Studies have shown that the thermal energy deposited on the vaginal wall stimulates neovascularization, improves natural lubrication and collagen synthesis with a significant improvement of vaginal health [6].

Short-term data regarding the use of fractionated CO₂ laser therapy demonstrated that this treatment appeared to be a feasible, effective and safe intervention for VVA symptoms even in patients with contraindications to hormonal treatments such as breast cancer survivors [7–10].

Long-term efficacy and safety data about this treatment option are lacking. Thus far, most studies report observed results after 12 weeks, with no further follow-up. Therefore, assumptions cannot yet be made regarding the durability of this treatment nor the long-term effects.

The purpose of this study is to evaluate long-term effects of a fractional CO₂ laser for the treatment of VVA.

Methods

This prospective cohort study was conducted between June 2013 and September 2016 at Centre of Gynecological Laser Surgery and Colposcopy of the University Teaching Hospital of Careggi in Florence. It included postmenopausal women, who had complained of one or more symptoms related to VVA and who underwent one or more vaginal treatments with fractional CO₂ laser.

Patients were asked to read and subscribe an information white paper illustrating physical principles of the technique, intraoperative and postoperative complications [11].

The type of informed consent used was specifically designed for the treatment of VVA with fractional microablative CO₂ laser in agreement with the Helsinki Declaration. The type of informed consent coupled the one previously used by other researching groups [10]. The patients entered the study, after the informed consent was obtained.

Enrolled patients accepted to undergo a gynecological visit before the first treatment. Gynecological visit included speculum insertion to measure vaginal elasticity and colposcopic inspection of the integrity of the epithelium.

The inclusion criteria consisted of menopause status (spontaneous menopause or menopause induced by chemotherapy or surgical adnexectomy), one or more VVA

symptoms (itching, burning, reduced lubrication, post-coital bleeding, and dyspareunia), negative Pap smear not older than a year or negative human papillomavirus (HPV) test not older than 5 years.

Exclusion criteria were considered the use of vaginal moisturizing agents and lubricants within 30 days before the inclusion in the study group; the presence of active genital infection during the visit at the enrollment; prolapse stage \geq II according to pelvic organ prolapse quantification system [12]; previous reconstructive pelvic surgery or topical radiotherapy, previous vulvar, vaginal or cervical cancer.

Each patient received three laser applications with the fractional microablative CO₂ laser (Smart Xide2; V2LR Monnalisa Touch System, DEKA Florence, Italy) at an interval 4 weeks between sessions: baseline (T1), 30 days (T2) and 60 days (T3). All laser applications were performed in an outpatient setting; they did not require local anesthesia or not other preparation. During each session, the laser energy was set at 30 W power and transmitted through an intravaginal probe with a dwell time of 1000 μ s, a dot spacing of 1000 μ m and a smart stack parameter of 1 following a protocol of application used in previous authors' study [7].

Laser energy was released by two single shots oriented at 45° one from the other so to treat the entire circular vaginal surface covered by the probe which is doted of two opposite focusing points.

Patients were not prohibited to have sexual activity before or after the treatment sessions.

The collection of the demographic characteristics of patients, verification of inclusion and exclusion criteria and evaluation of VVA presence were recorded at T1.

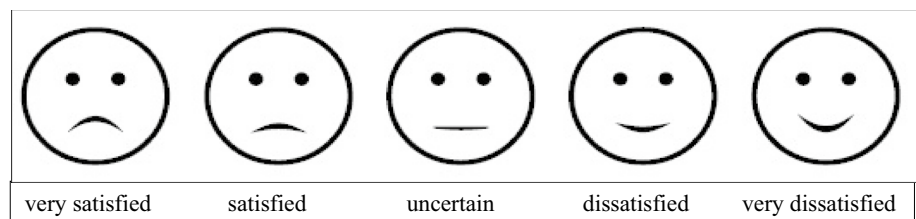
Any intraoperative complications (such as pain at probe insertion, burning, itching) and postoperative complications (such as bleeding, leucorrhea, discomfort) of the treatment were recorded.

Treatment satisfaction was evaluated at 4 weeks after the last laser application (T4), 6, 12, 18, 24 months after treatment. At each follow-up, the treatment satisfaction was evaluated using a five-point Likert scale (very satisfied, satisfied, uncertain, dissatisfied and very dissatisfied) (Fig. 1). This visual scale was chosen as a prolonged use of the same one in the authors' first manuscript [7] so to uniform the data among the entire patients' series and secondarily because women declared to be confident with this tool which they consider perfectly matching their symptoms.

Points to be evaluated were: recorded subjective symptoms during daily life as itching and burning; recorded dyspareunia; pain at probe insertion by the physician. Treatment was considered satisfactory when patients were very satisfied or satisfied.

Patients were further subdivided into two groups according to the cause of menopause: spontaneous menopause or menopause induced by chemotherapy or surgical

Fig. 1 Five-point Likert scale. This visual scale was chosen to evaluate the treatment satisfaction at each follow-up



adnexectomy. The objective was to analyze patient satisfaction with laser procedure in different time period in two study groups.

Statistical analysis by Student's *t* test was conducted on demographic parameters in the two groups to identify those which had influence in the treatment satisfaction. *P* values <0.05 were considered statistically significant.

A logistic regression was used to explain the relationship between the treatment satisfaction (dependent binary variable) and all collected demographic characteristics, took as independent variables, in a multivariate model.

Results

From June 2013 to September 2016, a total of 262 patients underwent treatment with the fractional microablative CO₂ laser for one or more symptoms related to VVA.

Out of 262 patients enrolled in the study, 12 patients were very dissatisfied with the treatment and decide to abandon the study. 66 women were excluded from the study because they were unavailable for long-term follow-up data.

184 patients constituted the final study group. These patients completed the study protocol and were available for long-term follow-up data.

The mean age of patients was 56 years (range 38–72) with a mean time of menopause at the enrollment of 8 years (range 1–25); among them 117 (63.6%) women were nulliparous, 36 (19.6%) had previous hysterectomy. We divided the enrolled patients in two groups depending on the cause of menopause: spontaneous menopause or menopause induced by chemotherapy or surgical adnexectomy. Of the 184 patients included in the study, 128 women were spontaneous menopause and 56 were oncological menopause (women with current or previous breast cancer). Demographic characteristics of the study group are summarized in Table 1.

The rate of treatment failure was 4.6% (12/262) at T4; all 12 patients presented diseases or chronic conditions associated with VVA that could interfere with study compliance: six patients were suffering from diabetes mellitus; four women were affected by Sjogren's syndrome, one patient by multiple sclerosis and the last by psoriasis.

Thus, patient's satisfaction with laser procedure at T4 was totally 95.4% (250/262): 74.8% (187/250) belonging to the

Table 1 Patients' demographic characteristics

Spontaneous menopause	128
Oncological menopause	56
Mean age	
Spontaneous menopause	57, 76
Oncological menopause	53, 76
Time from onset of menopause	
Spontaneous menopause	8, 8
Oncological menopause	6, 3
Nulliparous	117
Previous hysterectomy	36

satisfied category and 25.2% (63/250) to the very satisfied one.

Every enrolled patient was called in September 2016 to evaluate long-term treatment effects. The time of follow-up was between 6 and 24 month after treatment. 66.3% (122/184) of patients answered they wanted to repeat the treatment; 17.4% (32/184) decided to start or were making a new treatment cycle of laser applications; 16.3% (30/184) did not want to repeat the treatment.

Treatment satisfaction was evaluated every 6 months. At 6 months 92% (170/184) patients were satisfied; at 12 months 72% (118/162) were satisfied; at 18 months 63% (60/94) were satisfied; at 24 months 25% (4/16) of patients answered they were still satisfied. No patient declared to be very satisfied during the long-term follow-up.

Figure 2 shows patients' satisfaction rate during the follow-up period. We observed a change in patients' satisfaction between 18 and 24 months after laser therapy. This seems to be the time when treatment effects were reduced and women could decide to start a new treatment cycle of laser applications.

At 6 months 92% (118/128) of patients were satisfied in non-oncological group and 93% (52/56) were satisfied in oncological group; at 12 months 69% (78/112) of non-oncological patients and 80% (40/50) of oncological patients were satisfied; at 18 months 44% (22/50) of patients in spontaneous menopause and 86% (38/44) of patients in oncological menopause answered they were still satisfied. At 24 months treatment effects were found only in group of oncological menopause in 50% (4/8) of patients.

Patients' satisfaction differences were observed between two study groups (Fig. 3).

Fig. 2 Patients' satisfaction rate during the follow-up period. We observed a decline in patient's satisfaction between 18 and 24 months after laser therapy

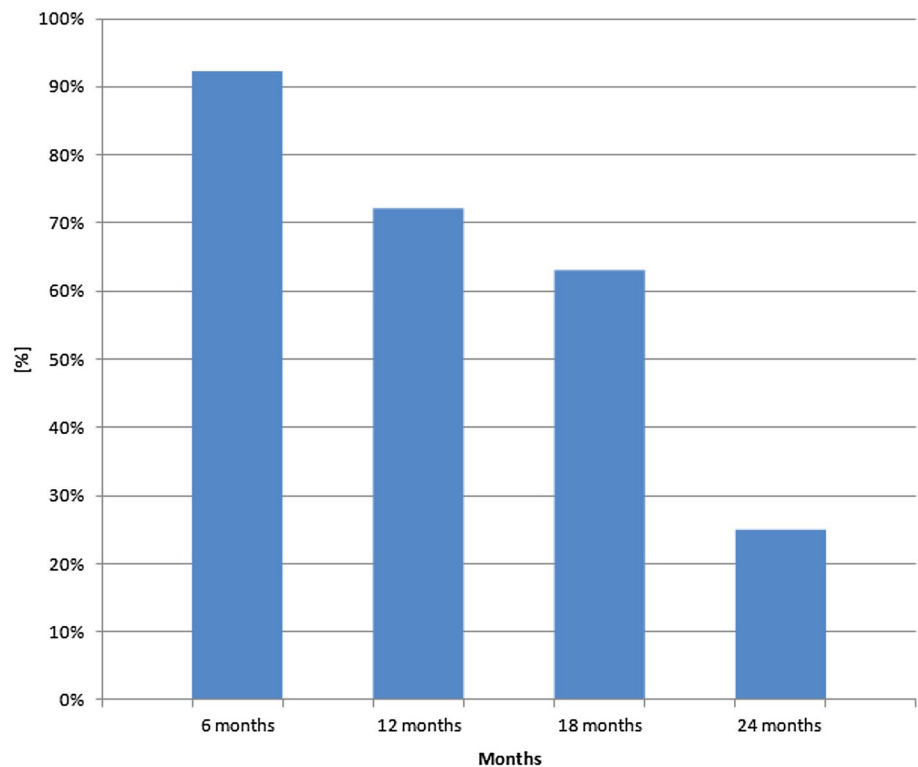
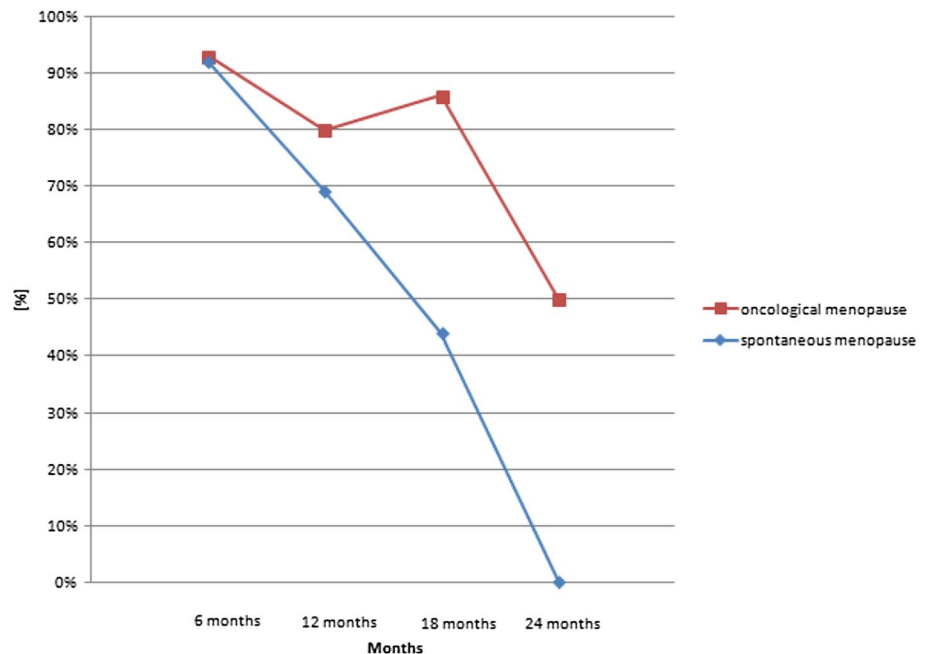


Fig. 3 Patients' satisfaction rate during follow-up period in two groups: spontaneous and oncological menopause



Interval time from onset of menopause and treatment resulted to be the only statistically significant factor ($p < 0.05$) influencing satisfaction within the oncological group, although at the multivariate analysis this did not emerge as a significant independent prognosticator of treatment success.

Discussion

The fractional CO₂ laser system produces two effects: a superficial vaporization and a deeper thermal effect with consequent histological modifications on the vaginal wall stimulated proliferation of the glycogen-enriched epithelium, neovascularization and the synthesis of new mature

collagen and matrix substance components. The healing process showed a first phase of inflammatory response with granulation tissue at 1–3 days post-treatment, followed by progressive neocollagenesis and dermal remodeling up to 30 days post-treatment. Neocollagenesis continued for several months thereafter [6].

Short-term data, 4 weeks after the end of treatment (T4), regarding the use of laser therapy has reported improvement in vulvovaginal symptoms, in the Vaginal Health Index Score, in sexual function, therefore in women's quality of life. Moreover, studies confirmed the safety, feasibility and efficacy of fractional CO₂ laser therapy in the treatment of VVA including breast cancer survivors, for whom estrogen treatment is contraindicated [7–10].

The data from our study confirmed the effectiveness of fractional CO₂ laser treatment and the short-term effects of the therapy at T4 which were demonstrated in previous studies. Therefore, the treatment with fractional CO₂ laser is feasible, safe and effective without adjuvant agents such as hormonal or non-hormonal vaginal moisturizers and lubricants in women who had complained of one or more symptoms related to VVA. In fact, 95.4% of the patients declared that they were satisfied or very satisfied with the procedure at T4.

12 patients (4.6%), who were very dissatisfied with the treatment at T4, were all affected by chronic conditions involving epithelium in autoimmune damage.

Thus to authors the treatment appeared to be less effective or completely ineffective in the tissues in which there is a chronic immunological damage or other impairment of the tissue compartment. This negative result is probably due to the presence of an extracellular matrix already altered in a condition of pre-menopause, on which, therefore, a thermal stimulus is not sufficient to reshape the amorphous substance.

The clinical improvement reported in these patients had a duration of 15–30 days. This effect is probably due to inflammatory response rather than to tissue remodeling after treatment.

This observation is of utmost importance because it explains the reason why the presence of any disease or chronic condition should be considered one of exclusion criteria of laser treatment.

Other studies [8, 10] considered the presence of chronic disease as an exclusion criterion because this might interfere with study compliance. The present study demonstrated that these patients are failing to the treatment; they have no indication to be eligible to it.

In 2017, study of Sokol et al. demonstrated for the first time in a small population that the therapy with fractional CO₂ laser induced durable positive effects out to 1 year for the treatment of VVA [13].

The latest study of Behnia-Willison et al. proved the efficacy of fractional microablative CO₂ laser treatment in

improving symptoms associated with genitourinary syndrome of menopause and quality of life at short- and long-term follow-up (between 12 and 24 months). The improvements in sexual function, dyspareunia and vaginal sensation and lubrication observed in the short term were maintained at long-term follow-up in postmenopausal women [14].

At our knowledge, this is the first study evaluating the long-term effects (up to 2 years) of fractional CO₂ laser treatment comparing the long-term effects in two different study groups: women in spontaneous menopause and women in oncological menopause.

Concerning the long-term follow-up data (from 6 to 24 months) the results show that the majority of patients (83.7%) would like to repeat the treatment, was doing a new cycle of treatment at the time of interview or had already done a new cycle. This result underlines the degree of long-term satisfaction and patients' confidence to treatment.

Furthermore, we observed a change in patient satisfaction between 18 and 24 months after laser therapy. This seems to be the latency when treatment effects are reduced and VVA symptoms reappear. For this reason authors argue that women could program a new cycle of laser applications at the 18th month after the end of treatment. The new cycle of treatment seems to be particularly appropriate in patients in spontaneous menopause because the analysis of the data shows that the clinical effects of treatment worsen significantly after 18 months in this group of patients. The clinical worsening appears to be less evident in oncological group at this time.

The comparison between the two study groups showed that the time interval from onset of menopause is a statistically significant factor in treatment satisfaction. In fact, oncological patients undergo treatment at a younger age than other women (mean age 53 versus 57 years), but they usually also do it after a shorter time interval from the last period than patients in spontaneous menopause (6 versus 9 years). This suggests that the time period spent in the absence of estrogenic stimulation can affect the tissue response to laser therapy. Therefore, the data suggest that the longer period elapsing between the onset of menopause and laser treatment worsen the long-term response of the vaginal wall to therapy.

In conclusion, our study is the first to explore the clinical long-term effects of fractional microablative CO₂ laser for a treatment of VVA on spontaneous and oncological menopause. The clinical effects of laser therapy persist until 18 months after treatment in patients in spontaneous menopause and may continue up to 24 months after treatment in oncological group. Thus, the fractional microablative CO₂ laser is a valid non-hormonal therapeutic option for symptoms of VVA. Finally, this study suggests to repeat a new cycle of treatment after 18 from the end of the first cycle with the aim to maintain the therapeutic effects.

The long-term effects of this treatment allows VVA symptoms relief without requiring daily or chronic drug intake, thus resulting in ensuring a better quality of life for women compared to chemical drugs.

Women of the study group confirmed fractional microablative CO₂ laser treatment to be a reliable not chronic therapy used to improve chronic symptoms of VVA.

The major limitation of the present study is that authors did not explore with histological evaluations the long-term effect on the vaginal wall so that results are expressed only as clinical long-term effects with no objective histology proving them.

The choice to keep a measurement tool which was considered good by patients was made to follow the evidence that empowerment models teaching self-control of personal health which improves patient satisfaction and compliance. The visual five-step Likert scale was furthermore chosen in respect of an empowerment of patient model requiring women to be viewed as experts of their own condition and responsible for decision [15].

Moreover, as all other studies reported in the literature, this study lacks a control arm to account for placebo effect and a comparison therapy. Therefore, additional studies with larger populations and placebo control are still needed.

Acknowledgements We thank DEKA M.E.L.A. S.r.l. for the technical support.

Author contribution Protocol/project development: AP, MGF. Data collection or management: SC, ML, AB. Data analysis: CB, NA, AP. Manuscript writing/editing: AP, CB. Administrative technical support/supervision: FP, GC.

Compliance with ethical standards

Conflict of interest The authors declare that they have no conflict of interest.

Ethical approval All procedures performed in studies involving human participants were in accordance with the ethical standards of the institutional and/or national research committee and with the 1964 Helsinki declaration and its later amendments or comparable ethical standards.

Informed consent Informed consent was obtained from all individual participants included in the study. The ethical approval and the informed consent have been specified above in the manuscript text.

References

- Portman DJ, Gass ML (2014) Vulvovaginal atrophy terminology consensus conference panel. *Genitourinary syndrome of menopause: new terminology for vulvovaginal atrophy from the International Society for the Study of Women's Sexual Health and the North American Menopause Society*. *Menopause* 21:1063–1068
- North American Menopause Society (2013) Management of symptomatic vulvovaginal atrophy: 2013 position statement of the North American Menopause Society (2013). *Menopause* 20:888–902
- Sturdee DW, Panay N, On behalf of the International Menopause Society Writing Group (2010) Recommendations for the management of postmenopausal vaginal atrophy. *Climacteric* 13:509–522
- Hutchinson-Colas J, Segal S (2015) Genitourinary syndrome of menopause and the use of laser therapy. *Maturitas* 82:342–345
- Del Pup L (2016) Ospemifene: a safe treatment of vaginal atrophy. *Eur Rev Med Pharmacol Sci* 20:3934–3944
- Tadir Y, Gaspar A, Lev-Sagie A, Alexiades M, Alinsod R, Bader A et al (2017) Light and energy based therapeutics for genitourinary syndrome of menopause: consensus and controversies. *Lasers Surg Med* 49:137–159
- Pieralli A, Fallani MG, Becorpi A, Bianchi C, Corioni S, Longinotti M, Tredici Z, Guaschino S (2016) Fractional CO₂ laser for vulvovaginal atrophy (VVA) dyspareunia relief in breast cancer survivors. *Arch Gynecol Obstet* 294:841–846
- Salvatore S, Nappi RE, Parma M, Chionna R, Lagona F, Zebinati N, Ferrero S, Origoni M, Candiani M, Leone Roberti Maggiore U (2015) Sexual function after fractional microablative CO₂ laser in women with vulvovaginal atrophy. *Climacteric* 18:219–225
- Perino A, Calligaro A, Forlani F, Tiberio C, Cucinella G, Svetlato A, Saitta S, Calagna G (2015) Vulvovaginal atrophy: a new treatment modality using thermos-ablative fractional CO₂ laser. *Maturitas* 80:296–301
- Salvatore S, Nappi RE, Zerinati N, Calligaro A, Ferrero S, Origoni M, Candiani M, Leone Roberti Maggiore U (2014) A 12-week treatment with fractional CO₂ laser for vulvovaginal atrophy: a pilot study. *Climacteric* 17:363–369
- Committee on Gynecologic Practice, American College of Obstetricians and Gynecologists. ACOG Committee Opinion No. 378 (2007) Vaginal “rejuvenation” and cosmetic vaginal procedures. *Obstet Gynecol* 110:737–738
- Persu C, Chapple CR, Cauni V, Gutue S, Geavlete P (2011) Pelvic organ prolapse quantification system (POP-Q)—a new era in pelvic prolapsed staging. *J Med Life* 4:75–81
- Sokol ER, Karram MM (2017) Use of a novel fractional CO₂ laser for the treatment of genitourinary syndrome of menopause: 1-year outcomes. *Menopause*. doi:10.1097/GME.0000000000000839
- Behnia-Willison F, Sarraf S, Miller J, Mohamadi B, Care AS, Lam A et al (2017) Safety and long-term efficacy of fractional CO₂ laser treatment in women suffering from genitourinary syndrome of menopause. *Eur J Obstet Gynecol Reprod Biol* 213:39–44
- Ciccone MM, Aquilino A, Cortese F, Scicchitano P, Sassara M, Mola E et al (2010) Feasibility and effectiveness of a disease and care management model in the primary health care system for patients with heart failure and diabetes (Project Leonardo). *Vasc Health Risk Manag* 6:297–305