

# Use of a novel fractional CO<sub>2</sub> laser for the treatment of genitourinary syndrome of menopause: 1-year outcomes

Eric R. Sokol, MD,<sup>1</sup> and Mickey M. Karram, MD<sup>2</sup>

---

## Abstract

**Objectives:** To assess safety and efficacy of a fractional CO<sub>2</sub> laser therapy for the treatment of genitourinary syndrome of menopause (GSM) with follow-up to 1 year posttreatment.

**Methods:** Women presenting with GSM and meeting inclusion criterion were enrolled. Visual Analog Scales were used to grade vaginal pain, burning, itching, dryness, dyspareunia, and dysuria. Dilators were used to rate vaginal elasticity at baseline and at each follow-up visit. Before each treatment and at follow-up, Vaginal Health Index scoring and Female Sexual Function Index questionnaires were completed. Women received three vaginal laser treatments spaced 6 weeks apart. Participant satisfaction was measured on 5-point Likert scales (1 = very dissatisfied, 5 = very satisfied).

**Results:** Of 30 women (mean age 58.6 ± 8.8 years), three were lost to follow-up at 3 months and six at 1 year. None were discontinued or withdrew due to an adverse event. Average improvement in Visual Analog Scale scores for all symptom categories was statistically significant at 3 months and remained so through 1 year, except dysuria. Differences between data at 3 months and 1 year were not statistically significant, indicating persistence of positive outcomes. Average overall improvement in pain was 1.9 (±3.4), burning 1.9 (±3.1), itching 1.4 (±1.9), dryness 5.9 (±2.8), dyspareunia 4.9 (±3.3), and dysuria 0.9 (±3.1). Improvement in average Vaginal Health Index and Female Sexual Function Index scores was also statistically significant ( $P < 0.0001$ ). Of 19 women undergoing dilator examination at 1 year, 18 (94.8%) were comfortable with the same or larger dilator size. Twenty-two of 24 women (92%) were satisfied or extremely satisfied with the treatment at 1 year.

**Conclusions:** Based on study data up to 1 year, the fractional CO<sub>2</sub> laser may be an effective and safe treatment for women suffering from symptoms of GSM, although additional studies with larger populations and placebo control is needed to confirm these results.

**Key Words:** Dyspareunia – Fractional CO<sub>2</sub> laser – Genitourinary syndrome of menopause – Menopause – Vaginal dryness – Vulvovaginal atrophy.

---

Genitourinary syndrome of menopause (GSM), also known as vulvovaginal atrophy (VVA), is a suite of conditions resulting from atrophy of vulvovaginal tissue, including the vaginal mucosa, due to the natural decrease in estrogen levels after the onset of menopause.<sup>1</sup> Reductions in diameter and elasticity of the vaginal canal and introitus, quality of vaginal tissue, and lubrication are common, with numerous secondary effects such as dryness and irritation, dyspareunia, sexual dysfunction, and dysuria.<sup>2,3</sup> Many women endure the reduced quality of life (QoL)

associated with GSM,<sup>4-6</sup> with some studies suggesting that up to 50% of postmenopausal women suffer from menopausal vulvovaginal symptoms.<sup>7</sup>

Although safe and effective treatments such as topical lubrication, ospemifene,<sup>8,9</sup> and vaginal hormone therapy (HT)<sup>10</sup> exist for GSM, energy-based treatment devices using methods similar to those employed to rejuvenate skin of the face and body are emerging as viable alternatives.<sup>11-15</sup> Research has demonstrated the viability of the use of fractional CO<sub>2</sub> lasers and their potential to successfully treat GSM.<sup>16-20</sup>

A recent US pilot study investigated the use of a fractional CO<sub>2</sub> laser for the treatment of symptoms of GSM, with reporting of data through follow-up at 3 months after the final treatment session.<sup>21</sup> Treatment is straightforward; after insertion into the vaginal canal, a burst of laser pulses (fractional treatment) is transmitted through the tubular vaginal probe and deflected at 90° in four directions (the 12, 3, 6, and 9 o' clock positions) toward vaginal wall tissue, then rotated clockwise 45° (to the 1:30 position) for a second burst of pulses. Guided by markings on the probe, the user withdraws the probe 4 mm and repeats the procedure until reaching the

---

Received September 26, 2016; revised and accepted December 13, 2016. From the <sup>1</sup>Urogynecology and Pelvic Reconstructive Surgery, Stanford University, Stanford, CA; and <sup>2</sup>Advanced Urogynecology and Pelvic Surgery, The Christ Hospital, Cincinnati, OH.

Funding/support: This trial was supported by DEKA M.E.L.A. Srl using the investigators' protocol, with oversight by the Stanford University IRB, and also The Christ Hospital IRB; women did not pay for treatment.

Financial disclosure/conflicts of interest: Dr Karram is a paid consultant of Cynosure, Inc. Dr Sokol has a relationship with American Medical Systems and has stock options from Pelavon.

Address correspondence to: Eric R. Sokol, MD, Stanford University School of Medicine, 300 Pasteur Drive, Room G332, Stanford, CA 94305. E-mail: esokol@stanford.edu

introtitus. Treatment parameters are modulated downward to participant tolerance, if required.

Results of this pilot study suggested high levels of safety, tolerability, and participant satisfaction with demonstrated efficacy at 3 months after treatment. We currently report safety and efficacy outcomes for women treated with a fractional CO<sub>2</sub> laser for symptomatic GSM 1 year after treatment.

## METHODS

As outlined in the original report,<sup>21</sup> this two-center study included 30 consecutive healthy, nonsmoking postmenopausal women, who presented with symptoms of GSM. Women had to exhibit bothersome symptoms of VVA, could not have menstruated for at least 12 months, had to have less than stage 2 prolapse according to the pelvic organ prolapse quantification (POP-Q) system, and could not have had any procedures in the anatomical area for the previous 6 months. The use of vaginal creams, moisturizers, lubricants, or homeopathic preparations was not permitted for at least 3 months before study commencement and throughout the entire study period. The investigation was conducted according to Good Practice Guidelines (GCP) and was IRB-approved. Informed consent was obtained from all participants.

Exclusion criteria included presence of pelvic organ prolapse greater than stage II by the POP-Q system; previous reconstructive pelvic surgery; history of acute infections, thrombophlebitis, keloid formation, or heart failure; use or anticipated use of anticoagulants or antiplatelet treatments, thrombolytics, vitamin E, or anti-inflammatory agents within 2 weeks before study treatment; concurrent use of medications that increase photosensitivity; and the presence of any disease, disease history, or chronic condition that could interfere with study compliance.

Six categories of VVA-associated symptoms (vaginal pain, burning, itching, dryness, dyspareunia, and dysuria) were tracked using an 11-point Visual Analog Scale (VAS) where 0 was the lowest level (none) and 10 was the highest level (extreme). Secondary outcome measures included Bachmann Vaginal Health Index (VHI)<sup>22</sup> scoring, dilator-based testing of vaginal wall elasticity (using XS/extra small, S/small, M/medium, and/or L/large dilators), Female Sexual Function Index (FSFI) questionnaire, general QoL via Short Form 12 (SF-12) specific questionnaire, and a 5-point Likert scale (1 = very difficult, 5 = very easy) rating physician difficulty in treatment. Participant satisfaction was graded using the Patient Global Impression of Improvement (PGI, also a 5-point Likert scale, where 1 = much worse, 5 = much better).

After baseline screening with initial outcomes measurements including assessment of maximum participant-acceptable dilator size and questionnaires, women received a series of three treatments using the fractional CO<sub>2</sub> laser system (SmartXide<sup>2</sup>, MonaLisa Touch, DEKA M.E.L.A. Srl, Florence, Italy) with 6 weeks ( $\pm 1$  week) between, each performed in an outpatient setting without analgesia or anesthesia. Treatment parameters included power 30W, dwell time 1000  $\mu$ s, 1000  $\mu$ m spacing, using normal scan mode, with

Smartstack settings of 1 for the first treatment, and 3 for the second and third treatments, with treatment parameters modulated downward to participant tolerance if necessary.

Participants were evaluated for side effects or complications, and asked to rate their level of discomfort during treatment (via VAS). Sexually active women were encouraged to avoid coitus for 3 days after treatment. Just before the second and third treatment, women completed the PGI. Follow-up at 3 months included reassessment of all pretreatment evaluations, and also an additional survey of overall satisfaction with the laser treatment using a 5-point Likert scale (1 = very dissatisfied, 5 = very satisfied).

At 1 year after final treatment, follow-up evaluations included vaginal examination (including dilator measure of vaginal elasticity), VHI, VAS rating of all six VVA symptom categories, FSFI, SF-12, and a complete satisfaction survey assessing perception of results using a 5-point Likert Scale (1 = very dissatisfied, 5 = very satisfied). As in the original study, statistical analysis included appropriate measures for statistical significance (Student's paired two-sample *t* test, standard cut-off for significance  $P < 0.05$ ) via Microsoft Excel.

## RESULTS

Participants were primarily white women with a mean age of  $58.6 \pm 8.8$  years, average onset of menopause at  $48.9 \pm 7.6$  years, and average age of onset of vulvar and vaginal atrophy symptoms at  $51.2 \pm 8.3$  years. Of the 30 women who initially enrolled, 3 women did not attend the 3-month posttreatment time point; 6 were considered lost to follow-up at the 1-year time point (missed scheduled visit). The original study previously reports all data through the 3-month posttreatment time point.<sup>21</sup> No women withdrew due to an adverse event.

Mild adverse events included mild to moderate pain post-treatment, resolving within 2 or 3 days ( $n = 2$ ), and slight bleeding for less than 1 day ( $n = 2$ ). Overall, the most improvement in symptoms as assessed by VAS was seen after the initial treatment session, with additional incremental improvement noted after treatments 2 and 3. Improvement was statistically significant at 3 months for all VVA categories. Of all categories, dryness and dyspareunia had the most improvement.<sup>21</sup> At 12 months, improvement continued to be statistically significant for all categories except dysuria. Average overall improvement in pain was  $1.9 (\pm 3.4)$ , burning  $1.9 (\pm 3.1)$ , itching  $1.4 (\pm 1.9)$ , dryness  $5.9 (\pm 2.8)$ , dyspareunia  $4.9 (\pm 3.3)$ , and dysuria  $0.9 (\pm 3.1)$ . Table 1 places these numbers alongside those from baseline and follow-up at 3 months. Differences between 3-month and 1-year results were not statistically significant, indicating that a long-term benefit was seen.

For secondary outcome measures, VHI baseline average was  $14.4 \pm 2.9$ , with overall average improvement of  $7.0 \pm 3.1$  at 3 months, which was statistically significant ( $P < 0.0001$ ); at 1 year, overall average improvement was  $7.0 \pm 3.7$  from baseline, which was also statistically significant ( $P < 0.0001$ ). FSFI baseline average was  $11.5 \pm 7.8$ , with

**TABLE 1.** Assessment of average change in symptoms of vulvovaginal atrophy at follow-up<sup>a</sup>

Symptom	Baseline	Three-mo follow-up			One-y follow-up			Three mos versus 1-y, <i>P</i>
	Mean score	Mean score	Improvement	<i>P</i>	Mean score	Improvement	<i>P</i>	
Pain	2.3 ± 3.1	0.6 ± 1.4	1.7 ± 3.2	0.009	0.5 ± 1.5	1.9 ± 3.4	0.01	0.4
Burning	2.3 ± 3.3	0.9 ± 1.9	1.4 ± 2.9	0.02	0.5 ± 1.9	1.9 ± 3.1	0.007	0.1
Itching	1.9 ± 2.1	0.5 ± 1.3	1.4 ± 1.9	0.001	0.5 ± 1.1	1.4 ± 1.9	0.002	0.7
Dryness	7.5 ± 2.5	1.4 ± 2.5	6.1 ± 2.7	<0.0001	1.5 ± 2.0	5.9 ± 2.8	<0.0001	0.3
Dyspareunia	8.2 ± 1.7	3.0 ± 2.9	5.2 ± 3.0	<0.0001	3.1 ± 3.1	4.9 ± 3.3	<0.0001	0.5
Dysuria	1.1 ± 2.5	0.0 ± 0.2	1.1 ± 2.4	0.04	0.4 ± 1.3	0.9 ± 3.1	0.2	0.2

<sup>a</sup>Improvement measured on a Visual Analog Scale (0-10, where 0 = none and 10 = extreme), listed as mean ± standard deviation. Cut-off for statistical significance was *P* > 0.05.

overall average improvement of 8.9 ± 7.3 at 3 months, which was statistically significant (*P* < 0.0001); at 1 year, overall average improvement from baseline was 10.6 ± 10.0, which was also statistically significant (*P* < 0.0001). SF-12 grading included scores weighted for physical and mental health. Baseline average (physical) was 51.6 ± 6.2, with overall average improvement from baseline of 1.6 ± 8.1 at 3 months, which was not statistically significant (*P* = 0.3); at 1 year, overall average improvement was 2.2 ± 7.5 from baseline, which was also not significant (*P* = 0.2). Baseline average (mental) was 49.9 ± 10.2, with overall average improvement of -2.6 ± 10.6 at 3 months, which was not significant (*P* = 0.2); at 1 year, overall average improvement was 4.8 ± 11.1 from baseline, which was also not statistically significant (*P* = 0.1). A more complete comparison of secondary outcomes is shown in Table 2.

Changes in vaginal elasticity were measured via gynecological examination with vaginal dilators. At baseline, 24 of 30 women (80%) could only accept the extra small or small dilator, and at 3 months, 23 of that subset could comfortably accept the medium or large dilator; 25 women (83%) saw an increase in comfortable dilator size from baseline to 3-month time point. At the 1-year time point, 19 women underwent dilator examination; 14 (73.7%) were comfortable with a larger dilator size, 4 (21.0%) were comfortable with the same dilator size, and 1 (5.3%) was comfortable with one size smaller.

Participant satisfaction at 3 months after the final treatment session was high, with 26 of 27 women (96.3%) reportedly satisfied (n = 10) or very satisfied (n = 16) with the laser treatment. Of the 24 women who followed up at 1 year, 22

(92%) said they were either satisfied (n = 10) or very satisfied (n = 12).

Overall, at 3 months, all women (100%) showed improvement in 4 of 6 VVA symptoms measured by VAS; 19 of 27 (70%) showed an improvement in 5 of 6 symptom categories. At the 1-year time point, 22 of 24 women (92%) showed improvement in 4 of 6 symptom categories, with 58% (14 of 24) showing improvement in 5 of 6 scales.

**DISCUSSION**

This study presents follow-up information on outcomes given in the original study,<sup>21</sup> based on further data obtained from the same group of women in the original investigation, minus those lost to follow-up (which were not due to adverse events).

Our results suggest persistent improvement in the bothersome symptoms of VVA associated with GSM 1 year after vaginal treatment with a novel fractional CO<sub>2</sub> laser. Overall improvements in vaginal pain, burning, and itching were noted at 1 year, with improvements in dyspareunia and vaginal dryness being most pronounced. Improvements in the VHI and sexual health functioning as measured by the FSFI showed similar resistance to change between 3 months and 1 year after final treatment, with minor degradation in vaginal elasticity as measured by vaginal dilators. Taken together, these results suggest a durable positive effect on the vaginal symptoms of GSM 1 year out from treatment with the fractional CO<sub>2</sub> laser. Randomized controlled trials comparing this laser therapy with other therapies, including vaginal HT, are currently in progress.

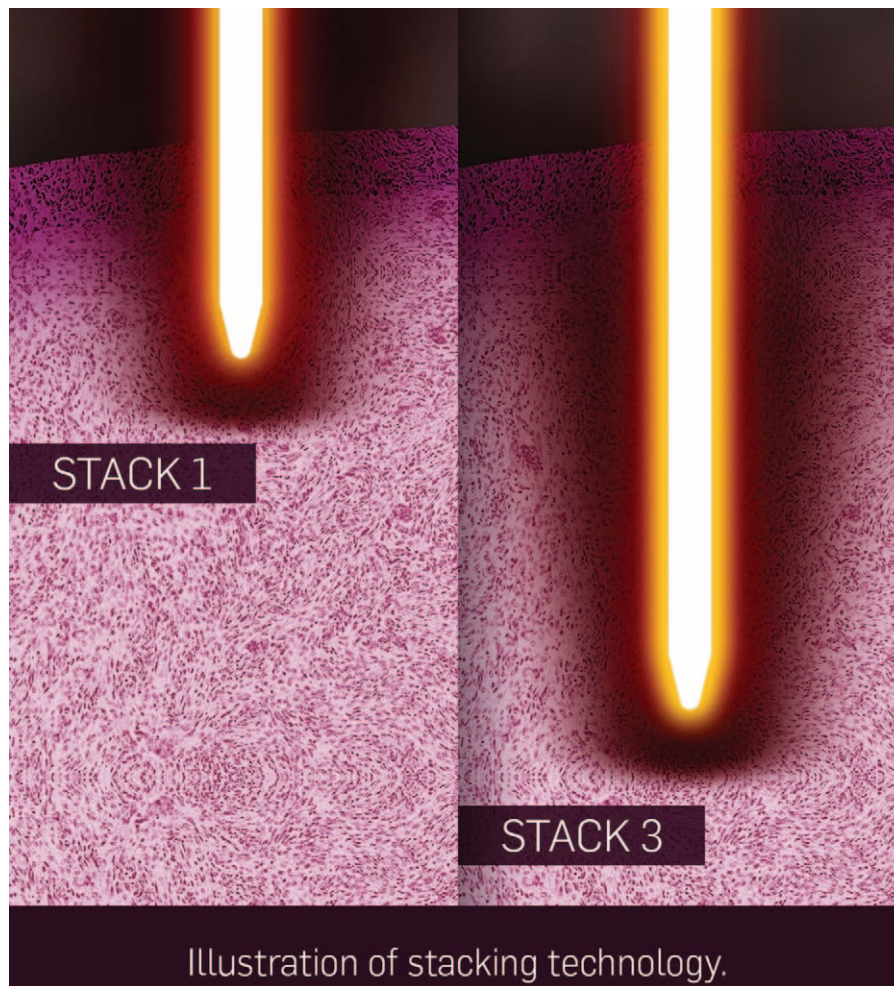
**TABLE 2.** Average change in secondary endpoints of VHI, FSFI, and SF-12 at follow-up versus baseline

Secondary endpoint <sup>a</sup>	Baseline	Three-mo follow-up			One-y follow-up			Three mos versus 1 y
	Mean score	Mean score	Improvement	<i>P</i>	Mean score	Improvement	<i>P</i>	<i>P</i>
VHI	14.4 ± 2.9	21.4 ± 2.9	7.0 ± 3.1	<0.0001	21.7 ± 3.6	7.0 ± 3.7	<0.0001	0.9
FSFI	11.5 ± 7.8	20.1 ± 11.0	8.9 ± 7.3	<0.0001	21.3 ± 11.5	10.6 ± 10.0	<0.0001	0.9
SF-12 (phys)	51.6 ± 6.2	53.0 ± 9.0	1.6 ± 8.1	0.3	53.6 ± 5.3	2.2 ± 7.5	0.2	1.0
SF-12 (mnt)	49.9 ± 10.2	47.0 ± 11.8	-2.6 ± 10.6	0.2	54.3 ± 7.9	4.8 ± 11.1	0.1	0.005

Items listed as mean ± standard deviation. Cut-off for statistical significance was *P* > 0.05.

FSFI, Female Sexual Function Index; SF-12 is general Quality of Life Questionnaire Short Form 12; VHI, Vaginal Health Index.

<sup>a</sup>SF-12 broken into weighted physical (phys) and mental (mnt) health components.



**FIG. 1.** A graphic representation of the effect of the SmartStack function of the treatment device (SmartXide<sup>2</sup>, MonaLisa Touch, DEKA M.E.L.A. Srl, Florence, Italy); depth of penetration at setting 3 (right) is greater than at setting 1 (left).

As detailed in the original study,<sup>21</sup> the application of fractional 10,600 nm CO<sub>2</sub> laser therapy for vulvovaginal tissue is a natural progression from previous, well-documented use of the modality in aesthetic medicine for remodeling of skin of the face, neck, and other areas. CO<sub>2</sub> and other lasers have been used to cause controlled thermal damage to skin, stimulating neocollagenesis and neoelastinogenesis to fortify the extracellular matrix (ECM).<sup>20</sup> Tissue of the vaginal wall is more vascular and more innervated than typical skin tissue, but is otherwise quite similar, and behaves similarly in response to thermal insult, suggesting a therapeutic vector. Recent studies using this and other wavelengths have demonstrated this concept.<sup>16-20</sup>

Fractional delivery of energy creates micro-wound patterns rather than causing damage via complete surface irradiation, leaving nearby skin and tissue structures undamaged. This reduces recovery time and downtime by promoting rapid re-epithelialization and healing. Each individual micro-wound may be ablative or coagulative (or some combination of the two), depending on the wavelength and energy level chosen.<sup>23</sup>

The device used for this trial has received US Food and Drug Administration (FDA) clearance for incision, excision, ablation, vaporization, and coagulation of soft tissue; its HiScan DOT scanner is indicated specifically to create highly controlled, uniform, layer-by-layer ablation without carbonization of tissue, with energy penetration as deep as 200  $\mu$ m. The probe allows 360° emission of energy. The SmartStack feature allows modulation of the depth of penetration of the laser beam in tissue to guarantee that, regardless of the conditions of the vaginal wall, emitted laser energy is always delivered to the lamina propria, through the epithelium, since that tissue layer is the actual target of the treatment. A graphic representation of the effect of SmartStack technology is given in Fig. 1.

This is a pilot study and should be interpreted as such. Limitations include a small and racially uniform participant population, lack of a control arm to account for placebo effect, and lack of comparison therapy. In the case of this 1-year follow-up study, an additional limitation was the loss to follow-up of a few more women. Nonetheless, this pilot study

suggests that vaginal treatment with a fractional CO<sub>2</sub> laser might be a viable and durable treatment option for some women suffering from GSM.

### CONCLUSIONS

The low risk of adverse events and durable positive effects out to 1 year suggest that fractional CO<sub>2</sub> laser therapy may be safe and effective for the treatment of VVA, also known as GSM. Given the small participant population and lack of a sham control, additional study to confirm these results using controlled clinical trials with larger populations will be beneficial and are underway.

### REFERENCES

1. Calleja-Agius J, Brincat MP. Urogenital atrophy. *Climacteric* 2009; 12:279-285.
2. Mehta A, Bachmann G. Vulvovaginal complaints. *Clin Obstet Gynecol* 2008;51:549-555.
3. Portman DJ, Gass MLS. Genitourinary syndrome of menopause: new terminology for vulvovaginal atrophy from the international society for the study of women's sexual health and the North American menopause society. *Menopause* 2014;21:1-6.
4. Pastore LM, Carter RA, Hulka BS, Wells E. Self-reported urogenital symptoms in postmenopausal women: women's health initiative. *Maturitas* 2004;49:292-303.
5. Santoro N, Komi J. Prevalence and impact of vaginal symptoms among postmenopausal women. *J Sex Med* 2009;6:2133-2142.
6. Kingberg SA, Wysocki S, Magnus L, Krychman ML. Vulvar and vaginal atrophy in postmenopausal women: findings from the REVIVE (REal Women's Views of Treatment Options for Menopausal Vaginal ChangEs) survey. *J Sex Med* 2013;10:1790-1799.
7. Erekson EA, Li FY, Martin DK, Fried TR. Vulvovaginal symptoms prevalence in postmenopausal women and relationship to other menopausal symptoms and pelvic floor disorders. *Menopause* 2016;23: 368-375.
8. Bachmann GA, Komi JO. Ospemifene effectively treats vulvovaginal atrophy in postmenopausal women: results from a pivotal phase 3 study. Ospemifene Study Group. *Menopause* 2010;17:480-486.
9. Wurz GT, Kao CT, Degregorio MW. Safety and efficacy of ospemifene for the treatment of dyspareunia associated with vulvar and vaginal atrophy due to menopause. *Clin Interv Aging* 2014;9:1939-1950.
10. Shulman LP, Portman DJ, Lee WC, et al. A retrospective managed care claims data analysis of medication adherence to vaginal estrogen therapy: implications or clinical practice. *J Women Health (Larchmt)* 2008; 17:569-578.
11. Tierney EP, Hanke CW. Ablative fractionated CO<sub>2</sub> laser resurfacing for the neck: prospective study and review of the literature. *J Drugs Dermatol* 2009;8:723-731.
12. Orringer JS, Rittié L, Baker D, Voorhees JJ, Fisher G. Molecular mechanisms of nonablative fractionated laser resurfacing. *Br J Dermatol* 2010;163:757-768.
13. Peterson JD, Goldman MP. Rejuvenation of the aging chest: a review and our experience. *Dermatol Surg* 2011;37:555-571.
14. Tierney EP, Hanke CW. Fractionated carbon dioxide laser treatment of photoaging: prospective study in 45 patients and review of the literature. *Dermatol Surg* 2011;37:1279-1290.
15. Ong MW, Bashir SJ. Fractional laser resurfacing for acne scars: a review. *Br J Dermatol* 2012;166:1160-1169.
16. Vizintin Z, Rivera M, Fistonich I, et al. Novel minimally invasive VSP Er:YAG laser treatments in gynecology. *J Laser Health Acad* 2012;1: 46-58.
17. Salvatore S, Nappi RE, Zerbinati N, et al. A 12-week treatment with fractional CO<sub>2</sub> laser for vulvovaginal atrophy: a pilot study. *Climacteric* 2014;17:363-369.
18. Perino A, Calligaro A, Forlani F, et al. Vulvo-vaginal atrophy: a new treatment modality using thermo-ablative fractional CO<sub>2</sub> laser. *Maturitas* 2015;80:296-301.
19. Salvatore S, Leone Roberti Maggiore U, Athanasiou S, et al. Histological study on the effects of microablative fractional CO<sub>2</sub> laser on atrophic vaginal tissue: an ex vivo study. *Menopause* 2015;22:845-849.
20. Zerbinati N, Serati M, Origoni M, et al. Microscopic and ultrastructural modifications of postmenopausal atrophic vaginal mucosa after fractional carbon dioxide laser treatment. *Lasers Med Sci* 2015;30:429-436.
21. Sokol ER, Karram MM. An assessment of the safety and efficacy of a fractional CO<sub>2</sub> laser system for the treatment of vulvovaginal atrophy. *Menopause* 2016;23:1102-1107.
22. Bachmann GA, Notelovitz M, Kelly SJ, et al. Long-term nonhormonal treatment of vaginal dryness. *Clin Pract Sex* 1992;8:12-17.
23. Hsiao F, Bock G, Eisen D. Recent advances in fractional laser resurfacing: new paradigm in optimal parameters and post-treatment wound care. *Adv Wound Care (New Rochelle)* 2012;1:207-212.